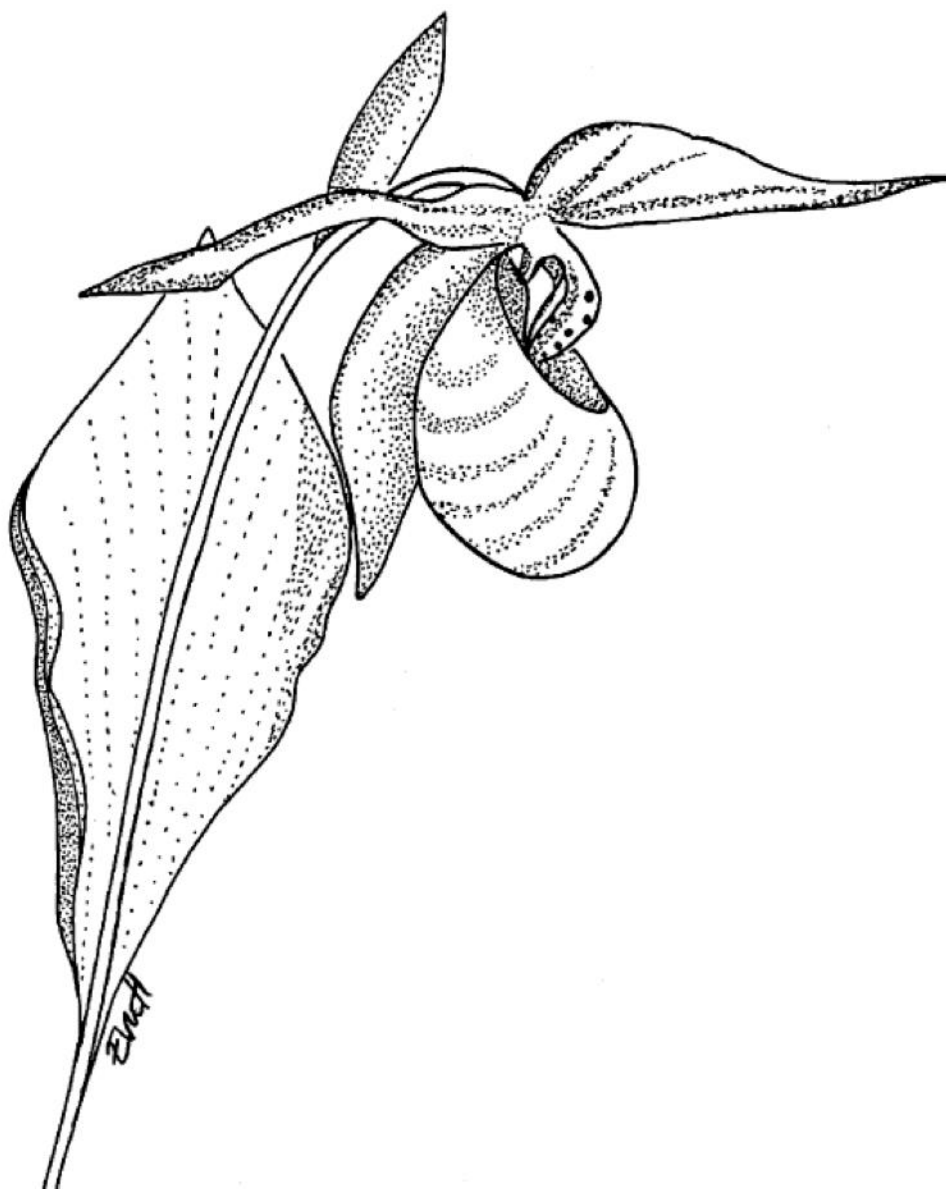


SWENOTECA X

A Cancer Care Program for
Germ Cell Tumours
(Including testicular, retroperitoneal and mediastinal tumours)



SWENOTECA WORKING GROUP

The SWENOTECA X cancer care program is developed by the working group of SWENOTECA in collaboration with Lennart Blomqvist, MD, PhD, Department of Imaging and Physiology Karolinska University Hospital and Erik Rud, MD, PhD, Department of Radiology and Nuclear Medicine, Oslo University Hospital, Oslo for the imaging part and Monika Eidem, MD, The Cancer Clinic, St. Olavs University Hospital, Trondheim, for the radiotherapy part.

Members of the SWENOTECA working group responsible for this program

- Torggrim Tandstad MD, PhD, Chairman SWENOTECA, Oncologist, The Cancer Clinic, St. Olavs University Hospital and Assistant Professor, NTNU, Trondheim
- Gabriella Cohn Cedermark, MD, PhD, Co-chairman SWENOTECA, Oncologist, Department of Urooncology, Karolinska University Hospital and Assistant Professor, Department of Oncology-Pathology, Stockholm
- Ingrid Glimelius, MD, PhD, Oncologist, Secretary SWENOTECA, Department of Oncology, Uppsala University Hospital, and Assistant Professor, Uppsala University, Uppsala
- Bjarte Almås, MD, Urologist, Department of Urology, Haukeland University Hospital
- Olav Dahl, MD, PhD, Oncologist, Department of Oncology, Haukeland University Hospital, and Professor, Bergen University, Bergen
- Axel Gerdtsson, MD, Urologist, Department of Urology, Skånes University Hospital, Malmö
- Anna Grenabo Bergdahl, MD, PhD, Urologist, Department of Urology, Sahlgrenska University Hospital, Department of Urology, Gothenburg
- Dag Halvorsen, MD, Urologist, Department of Urology, St. Olavs University Hospital, Trondheim, Norway
- Hege Sagstuen Haugnes, MD, PhD, Oncologist, Department of Oncology, University Hospital of North Norway, and Professor, UiT-The Arctic University of Norway, Tromsø
- Annika Hedlund, MD, Oncologist, Department of Oncology, Sahlgrenska University Hospital, Gothenburg
- Martin Hellström, MD, Oncologist, Department of Oncology, Norrland University Hospital, Umeå
- Göran Holmberg, MD, PhD, Urologist, Department of Urology, Sahlgrenska University Hospital, Gothenburg
- Ása Karlsdóttir, MD, PhD, Oncologist, Department of Oncology, Haukeland University Hospital, Bergen
- Anders Kjellman, MD, PhD, Urologist, Department of Urology, Karolinska University Hospital and CLINTEC, Karolinska Institutet, Stockholm
- Carl W. Langberg, MD, PhD, Oncologist, Department of Oncology, Oslo University Hospital, Oslo

- Signe Melsen Larsen, MD, Urologist, Department of Urology, Oslo University Hospital, Oslo
- Helene Francisca Stigter Negaard, MD PhD, Oncologist, Department of Oncology, Oslo University Hospital, Oslo
- Olof Ståhl, MD, PhD, Oncologist, Department of Oncology, Skånes University Hospital, Lund
- Rolf Wahlqvist, MD, PhD, Department of Urology, Oslo University Hospital, Oslo
- Anna Thor, MD, Urologist, Department of Urology, Karolinska University Hospital and CLINTEC, Karolinska Institutet, Stockholm

1	<u>PURPOSE OF THE SWENOTECA X CANCER CARE PROGRAM.....</u>	10
2	<u>ABBREVIATIONS</u>	12
3	<u>FLOWCHART: DIAGNOSIS, STAGING AND TREATMENT.....</u>	14
4	<u>BACKGROUND</u>	15
4.1	GENERAL INFORMATION	15
5	<u>DIAGNOSIS AND CLINICAL STAGING</u>	16
5.1	DIAGNOSIS.....	16
5.1.1	PROCEDURES BEFORE ORCHIECTOMY	16
5.1.2	CLINICAL EXAMINATION OF THE TESTES	16
5.1.3	SERUM TUMOUR MARKERS	16
5.1.3.1	Beta-human chorionic gonadotropin (β -hCG).....	16
5.1.3.2	Alpha-fetoprotein (AFP).....	17
5.1.3.3	Lactate dehydrogenase (LDH)	17
5.1.3.4	Placental alkaline phosphatase (PLAP).....	17
5.1.3.5	MicroRNA (MIR371-374)	18
5.2	FERTILITY MEASURES AND HORMONAL ANALYSES.....	18
5.3	INGUINAL EXPLORATION, ORCHIECTOMY AND BIOPSY.....	18
5.3.1	HEMISCROTECTOMY	19
5.3.2	ORGAN-SPARING SURGERY.....	19
5.3.3	BIOPSY OF THE CONTRALATERAL TESTIS	19
5.3.4	MICROLITHIASIS	20
5.4	MANAGEMENT OF GCNIS	20
5.4.1	GUIDELINES FOR FOLLOW-UP AFTER TESTICULAR IRRADIATION FOR GCNIS	21
5.5	INCIDENTAL FINDING OF SMALL LESIONS IN TESTIS	21
5.6	PATHOLOGICAL EXAMINATION OF THE TESTIS	21
5.7	STAGING INVESTIGATIONS.....	22
5.7.1	PATIENTS WITH SLIGHTLY ENLARGED PARAAORTIC LYMPH NODES/SUSPECTED METASTASES IN PRESUMED CLINICAL STAGE IIA MARKER NEGATIVE	23
6	<u>IMAGING.....</u>	24
6.1	DIAGNOSIS AND STAGING	24
6.2	TREATMENT EVALUATION	24
6.3	FOLLOW-UP.....	25
7	<u>CLINICAL STAGE I</u>	26

7.1	SEMINOMA	26
7.1.1	BACKGROUND SEMINOMA CLINICAL STAGE I	26
7.1.2	THE SWENOTECA EXPERIENCE SEMINOMA CS I	26
7.1.3	SURVEILLANCE	26
7.1.4	ADJUVANT CARBOPLATIN	27
7.1.5	ADJUVANT RADIOTHERAPY	27
7.1.6	TREATMENT RECOMMENDATIONS SEMINOMA CLINICAL STAGE I	27
7.2	NONSEMINOMA	28
7.2.1	BACKGROUND NONSEMINOMA CLINICAL STAGE I	28
7.2.2	THE SWENOTECA EXPERIENCE NONSEMINOMA CS I	28
7.2.3	SURVEILLANCE	29
7.2.4	ADJUVANT BEP	29
7.2.5	PRIMARY NERVE SPARING RETROPERITONEAL LYMPH NODE DISSECTION (RPLND)	29
7.2.6	TREATMENT RECOMMENDATIONS NONSEMINOMA CLINICAL STAGE I	29
8	<u>METASTATIC DISEASE</u>	<u>31</u>
8.1	GENERAL COMMENTS METASTATIC DISEASE	31
8.2	METASTATIC SEMINOMA	31
8.2.1	THE SWENOTECA EXPERIENCE CS II-IV SEMINOMA	32
8.2.2	CLINICAL STAGE IIA-IIB (≤ 3 cm) SEMINOMA	32
8.2.2.1	Primary RPLND	33
8.2.2.2	Preoperative FDG-PET CT	33
8.2.2.3	Chemotherapy	33
8.2.2.4	Radiotherapy IIA/IIB	33
8.2.2.5	Treatment recommendations clinical stage IIA + IIB ≤ 3 cm seminoma, 1-2 metastatic lymph nodes	34
8.2.3	CLINICAL STAGE IIB (>3 cm) - IV SEMINOMA	34
8.2.3.1	Good prognosis seminoma, clinical stage IIB (>3 cm) - IV	34
8.2.3.2	Treatment recommendations good prognosis seminoma clinical stage IIB (>3 cm) - IV	35
8.2.4	INTERMEDIATE PROGNOSIS SEMINOMA	35
8.2.4.1	Treatment recommendations intermediate prognosis seminoma	35
8.2.5	POST-CHEMOTHERAPY RESIDUAL MASSES SEMINOMA	36
8.3	METASTATIC NONSEMINOMA	36
8.3.1	TREATMENT RECOMMENDATIONS METASTATIC NONSEMINOMA	37
8.3.2	THE SWENOTECA EXPERIENCE CS II-IV NONSEMINOMA	37
8.3.3	GOOD PROGNOSIS NONSEMINOMA	38
8.3.3.1	Clinical Stage IIA nonseminoma Mk-	38
8.3.3.2	Treatment recommendations nonseminoma CS IIA Mk-	38
8.3.3.3	Treatment recommendations good prognosis nonseminoma, except CS IIA Mk-	39
8.3.4	INTERMEDIATE PROGNOSIS NONSEMINOMA	39
8.3.4.1	Treatment recommendations intermediate prognosis nonseminoma	39
8.3.5	POOR PROGNOSIS NONSEMINOMA	40
8.3.5.1	Treatment recommendations poor prognosis nonseminoma	40
8.3.5.2	Comments to the treatment of poor prognosis nonseminoma	41

8.4	BRAIN METASTASES	42
8.4.1	TREATMENT RECOMMENDATIONS BRAIN METASTASES.....	43
8.5	BONE METASTASES	43
9	<u>CHEMOTHERAPY</u>	<u>44</u>
9.1	CONVENTIONAL DOSE CHEMOTHERAPY	44
9.1.1	CISPLATIN	44
9.1.2	ETOPOSIDE.....	44
9.1.3	BLEOMYCIN	44
9.1.3.1	Treatment of Bleomycin Induced Pneumonitis.....	44
9.1.3.2	Bleomycin and anaesthesia	45
9.1.3.3	Bleomycin and scuba diving	45
9.2	HIGH-DOSE CHEMOTHERAPY WITH STEM CELL SUPPORT	45
9.2.1	THE SWENOTECA HDCT EXPERIENCE	45
9.2.2	HDCT REGIMENS	46
9.2.3	TREATMENT RECOMMENDATIONS HIGH-DOSE CHEMOTHERAPY.....	46
9.2.4	STEM CELL HARVEST AND PRACTICAL CONSIDERATIONS	47
9.3	G-CSF	47
9.4	THROMBOEMBOLIC EVENTS	47
9.4.1	RECOMMENDATIONS THROMBOPROPHYLAXIS.....	48
10	<u>SURGERY OTHER THAN ORCHIECTOMY</u>	<u>49</u>
10.1	RETROPERITONEAL LYMPH NODE DISSECTION (RPLND)	49
10.1.1	INDICATIONS.....	49
10.1.2	RPLND TEMPLATES.....	49
10.1.2.1	Right unilateral template.....	50
10.1.2.2	Left unilateral template	50
10.1.2.3	Bilateral template	50
10.2	SURGICAL APPROACH	50
10.2.1	PRIMARY RPLND	50
10.2.1.1	PC-RPLND in nonseminoma.....	50
10.2.1.2	PC-RPLND (seminoma).....	50
10.3	PATHOLOGY RESULTS	51
10.4	RETROGRADE EJACULATION	51
10.5	EXTRA-RETROPERITONEAL RESECTIONS	51
10.6	SURGERY AT RELAPSE AND TREATMENT FAILURE	52
10.6.1	NONSEMINOMA.....	52
10.6.1.1	Marker negative (Mk-) and late relapses	52
10.6.1.2	Surgery after 2nd line or later chemotherapy.....	52
10.6.2	SEMINOMA	52
10.6.3	PATIENTS WITH RESIDUAL DISEASE AFTER 2ND LINE CHEMOTHERAPY.....	52
10.6.4	SURGERY AT LATE RELAPSE	53

10.7	SURGICAL CONSIDERATIONS.....	53
<u>11</u>	<u>EXTRAGONADAL GERM CELL TUMOURS</u>	<u>54</u>
11.1	CLASSIFICATION AND PROGNOSIS	54
11.2	DIAGNOSTICS.....	54
11.3	TREATMENT.....	55
11.3.1	CHEMOTHERAPY	55
11.3.2	SURGERY.....	56
11.3.3	SALVAGE TREATMENT.....	56
11.3.4	REGISTRATION AND FOLLOW-UP	56
<u>12</u>	<u>FOLLOW-UP.....</u>	<u>57</u>
<u>13</u>	<u>TREATMENT OF RELAPSE OR PROGRESSION AFTER STANDARD COMBINATION</u>	
	<u>CHEMOTHERAPY</u>	<u>58</u>
13.1	RELAPSE AFTER SURVEILLANCE OR ADJUVANT CHEMOTHERAPY	58
13.2	RELAPSE AFTER INITIAL RADIOTHERAPY	58
13.3	PROGNOSIS OF RELAPSE OR PROGRESSION	58
13.4	CONVENTIONAL DOSE SALVAGE CHEMOTHERAPY	59
13.5	HDCT SALVAGE TREATMENT	59
13.6	TREATMENT OF RELAPSE.....	60
13.7	SALVAGE TREATMENT METASTATIC DISEASE	60
13.8	POST-CHEMOTHERAPY SURGERY OR RADIOTHERAPY	61
13.8.1	NONSEMINOMA.....	61
13.8.2	SEMINOMA	61
13.9	PALLIATIVE TREATMENT.....	61
<u>14</u>	<u>LONG-TERM COMPLICATIONS AND FOLLOW-UP AFTER TREATMENT FOR TESTICULAR CANCER</u>	
	<u>62</u>	
14.1	CONTROLS AT THE GENERAL PRACTITIONER.....	62
14.2	CARDIOVASCULAR DISEASE (CVD).....	62
14.3	SECOND CANCER.....	63
14.4	FERTILITY AND HYPOGONADISM.....	63
14.4.1	FERTILITY	63
14.4.2	RETROGRADE EJACULATION.....	64
14.4.3	HYPOGONADISM	64
14.4.3.1	Examinations.....	64
14.4.3.2	Treatment	65
14.5	FATIGUE	65
14.6	OTHER LONG-TERM COMPLICATIONS	66
14.6.1	OTOTOXICITY.....	66

14.6.2	NEUROTOXICITY	66
14.6.3	RAYNAUD'S PHENOMENON.....	66

15 STROMAL TESTICULAR TUMOURS 67

15.1	LEYDIG CELL TUMOUR.....	67
15.1.1	DIAGNOSIS	68
15.1.2	TREATMENT	68
15.2	SERTOLI CELL TUMOURS.....	68
15.2.1	DIAGNOSIS	68
15.2.2	TREATMENT	69
15.3	GRANULOSE CELL TUMOURS	69
15.4	FIBROTHEROMA.....	69
15.5	GONADOBLASTOMA	69
15.6	OTHER TESTICULAR TUMOURS.....	69
15.7	SPERMATOCYTIC TUMOURS	69
15.8	FOLLOW UP	70

16 RADIOTHERAPY 71

16.1	FIELDS AND DOSES	71
16.1.1	SEMINOMA CS I.....	71
16.2	SEMINOMA CS II	71
16.3	PATIENT POSITION AND FIXATION.....	71
16.4	RADIOTHERAPY TREATMENT TECHNIQUE.....	71
16.4.1	BEAM QUALITY.....	72
16.4.2	TARGET VOLUMES AND ORGANS-AT-RISK (OAR) VOLUMES	72
16.4.3	TARGET VOLUMES	72
16.4.4	ORGANS AT RISK.....	72

17 PATIENT INFORMATION..... 73

18 APPENDIX..... 74

I.	PROGNOSTIC RISK GROUP CLASSIFICATION ACCORDING TO IGCCCG	74
II.	CLINICAL STAGING ACCORDING TO ROYAL MARSDEN, MODIFIED	75
III.	FLOWCHART RPLND CLINICAL STAGE IIA-IIB (≤ 3 CM) SEMINOMA.....	76
IV.	FLOWCHART METASTATIC SEMINOMA GOOD PROGNOSIS, EXCLUDING CLINICAL STAGE IIA-IIB (≤ 3 CM) SUITABLE FOR SURGERY	77
V.	FLOWCHART METASTATIC SEMINOMA INTERMEDIATE PROGNOSIS.....	78
VI.	FLOWCHART NONSEMINOMA CS IIA Mk- AT DIAGNOSIS/STAGING.....	79
VII.	FLOWCHART METASTATIC NONSEMINOMA GOOD PROGNOSIS, EXCLUDING CS IIA Mk-.....	80
VIII.	FLOWCHART METASTATIC NONSEMINOMA INTERMEDIATE AND POOR PROGNOSIS, EXCLUDING NON-PULMONARY VISCERAL METASTASIS OR PRIMARY MEDIASTINAL TUMOUR¹	81

IX. FLOWCHART METASTATIC NONSEMINOMA POOR PROGNOSIS WITH NON-PULMONARY VISCERAL METASTASIS OR PRIMARY MEDIASTINAL TUMOUR	82
X. FLOWCHART EXTRAGONADAL GERM CELL TUMOURS	83
XI. FLOWCHART BRAIN METASTASES AT DIAGNOSIS	84
XII. FLOWCHART BRAIN METASTASES AT RELAPSE AFTER CR	85
XIII. FLOWCHART SALVAGE TREATMENT INITIAL METASTATIC DISEASE	86
XIV. FOLLOW-UP SCHEDULE FOR SEMINOMA PATIENTS.....	87
XV. FOLLOW-UP SCHEDULE FOR NONSEMINOMA PATIENTS STAGE I, SURVEILLANCE	88
XVI. FOLLOW-UP SCHEDULE FOR NONSEMINOMA PATIENTS STAGE I, ADJUVANT BEP	89
XVII. FOLLOW-UP SCHEDULE FOR NONSEMINOMA PATIENTS AFTER TREATMENT FOR METASTATIC OR RECURRENT DISEASE 90	
XVIII. PATIENT CARE PLAN	91
XIX. MRI PROTOCOL	92
XX. BEP	93
XXI. EP	95
XXII. CARBOPLATIN	97
XXIII. TIP	99
XXIV. PEI	101
XXV. GOP	103
XXVI. EMA-CO	105
XXVII. CE HIGH DOSE CHEMOTHERAPY WITH AUTOLOGOUS STEMCELL SUPPORT	107
XXVIII. β -HCG HALF LIFE CHART	108
XXIX. AFP HALF LIFE CHART	109
<u>REFERENCES.....</u>	<u>110</u>

1 PURPOSE OF THE SWENOTECA X CANCER CARE PROGRAM

General purposes:

- Establish a complete register including all male adolescent (≥ 16 years) and adult patients with testicular, retroperitoneal and mediastinal germ cell cancer in Norway and Sweden
- Standardise diagnostic procedures, staging, treatment and follow-up in order to:
 - Improve patient outcome
 - Assure high quality prospective population-based clinical research

Specific foci in clinical stage I:

Seminoma

- Verify reported low relapse rate without adjuvant chemotherapy in patients with testicular tumour ≤ 4 cm and no stromal invasion of the rete testis
- Evaluate the relapse rate with and without adjuvant chemotherapy, respectively, in patients with testicular tumour > 4 cm and/or stromal invasion of the rete testis
- Further reduce the follow-up schedule depending on the risk and pattern of relapse
- Evaluate early and late toxicity after one course of adjuvant carboplatin

Nonseminoma

- Risk-adapted treatment: adjuvant one course of BEP, or surveillance
- The relapse rate and pattern of relapse for the presumed low-risk patients and high-risk patients respectively
- The early and late toxicity after adjuvant chemotherapy versus after treatment in case of relapse respectively

Specific foci in metastatic disease:

Seminoma

- Evaluate therapeutic efficacy and early and late toxicity of BEP chemotherapy
- Evaluate the efficacy of primary surgery for non-bulky CS IIA + IIB ≤ 3 cm seminoma, with 1-2 metastatic lymph nodes
- Evaluate the sensitivity and specificity of FDG-PET in the above-mentioned setting
- Evaluate the early and long-term side-effects of primary surgery

Nonseminoma

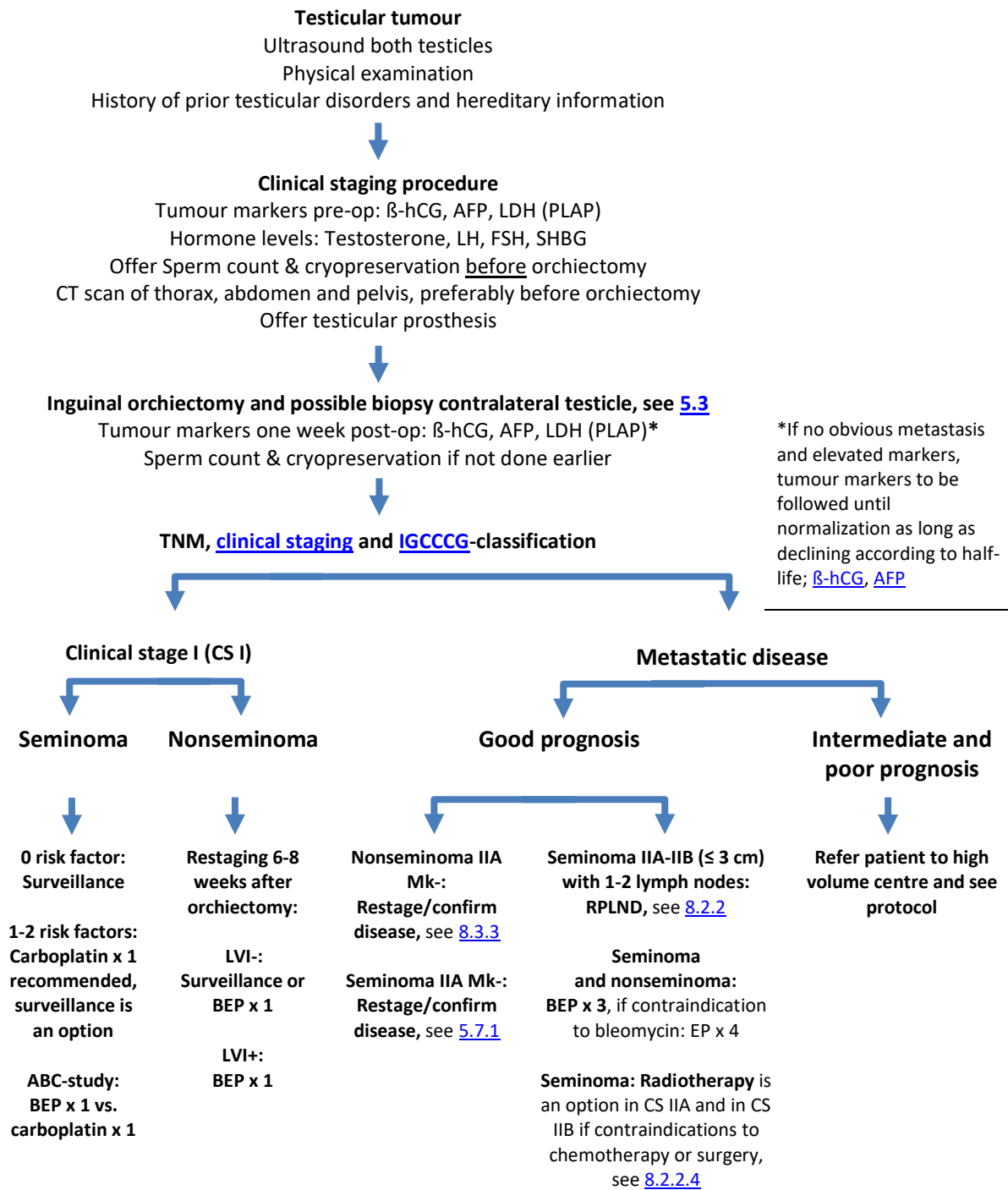
- Individualized treatment of metastatic disease according to risk group and initial tumour marker decline
- Reduce overtreatment where possible, and intensifying treatment in those with intermediate or poor prognosis or in poor responders
- Evaluate primary surgery in marker negative clinical stage II A patients
- To evaluate treatment outcome, time to relapse, the histological type of the recurrence, and the response to salvage therapy
- To evaluate early and late side effects after treatment for advanced disease

2 Abbreviations

AFP	Alpha fetoprotein
AUC	Area under the curve
BED	Biologically effective dose
BEP	Bleomycin, etoposide, cisplatin
BIP	Bleomycin-induced pneumonitis
CE	Carboplatin, etoposide
CR	Complete remission
CS	Clinical stage
CSS	Cancer specific survival
CT	Computed tomography
eGFR	Estimated glomerular filtration rate
EAU	European Association of Urology
EGCC	Extragenital germ cell cancer
EGCCCG	European Germ Cell Cancer Consensus Group
EMA-CO	Etoposide, methotrexate, actinomycin, cyclophosphamide, oncovin
EP	Etoposide, cisplatin
FDG-PET	Fluorodeoxyglucose Positron emission tomography
FSH	Follicle-stimulating hormone
FU	Follow-up
GCNIS	Germ cell neoplasia in situ
GCC	Germ cell cancer
G-CSF	Granulocyte colony-stimulating factor
GFR	Glomerular filtration rate
GOP	Gemcitabine, oxaliplatin, paclitaxel
β-hCG	Beta-human chorionic gonadotropin
HDCT	High-dose chemotherapy
IGCCCG	International Germ Cell Cancer Collaborative Group

IPFSC	International Prognostic Factors Study Group
LDH	Lactate dehydrogenase
LH	Luteinizing hormone
LVI	Lymphovascular invasion
Mk	Tumormarkers
MRC	Medical Research Council
MRI	Magnetic resonance imaging
NSGCT	Nonseminomatous germ cell tumour
OS	Overall survival
PC-RPLND	Post-chemotherapy retroperitoneal lymph node dissection
PEI	Cisplatin, etoposide, ifosfamide
PFI	Progression free interval
PFS	Progression free survival
PLAP	Placental alkaline phosphatase
RMH	Royal Marsden Hospital
RPLND	Retroperitoneal lymph node dissection
SGCT	Seminomatous germ cell tumour
SHBG	Sex hormone-binding globulin
SIB	Simultaneous integrated boost
SRT	Stereotactic radiotherapy
SWENOTECA	Swedish & Norwegian Testicular Cancer Group
TCS	Testicular cancer survivors
TGCC	Testicular germ cell cancer
TM	Tumour markers
TIP	Paclitaxel, ifosfamide and cisplatin
ULN	Upper limit of normal
VMAT	Volumetric modulated arc therapy
WBRT	Whole brain radiation therapy
WHO	World Health Organization

3 Flowchart: Diagnosis, Staging and Treatment



*If no obvious metastasis and elevated markers, tumour markers to be followed until normalization as long as declining according to half-life; [\$\beta\$ -hCG](#), [AFP](#)

Nonseminoma: All patients must be evaluated for post-chemotherapy resection at a high-volume centre

Seminoma: Remaining post-chemotherapy lesions should be evaluated in regard to need of PET-CT

4 Background

4.1 General Information

Testicular cancer accounts for 1-2 % of all malignancies, but despite its rarity it is the most common cancer in young men. The incidence is 6.2/100 000 in Western Europe and highest in the Nordic countries except Finland, with an incidence of 11.7/100 000 in Norway and 8.8/100 000 in Sweden. Approximately 650 new cases were diagnosed in 2018, with 350 in Sweden and 317 in Norway (1, 2).

Ninety-five percent of all testicular cancers are germ cell tumours of which 55-60 % are seminomas and 40-45 % are nonseminomas. The peak age incidence for seminoma patients is 38 years, ten years older than that for the nonseminoma patients. Despite all efforts the aetiology is still unknown but coupled to aberrations in the development of the gonads (e.g. cryptorchidism, poor semen quality), indicating an early in utero first step oncogenesis.

Seminomas have a monomorphic pathology with one cell-type derived from extra-embryonic tissue therefore true seminomas are not compatible with elevated levels of alpha-fetoprotein (AFP). In contrast the complex nonseminomatous germ cell tumours (NSGCT) may consist of a mixture of different cell types originating from the totipotent embryonic tissue and can also include elements of seminoma.

Seminomas are biologically different from NSGCT, reflected in the higher rate of clinical stage (CS) I disease at diagnosis, 85 % compared to 60 % in NSGCT. Seminomas are never classified as belonging to the poor prognosis group (3), see [appendix I](#) for prognostic groups.

Despite many patients having metastatic disease at diagnosis, the prognosis of testicular cancer is excellent. The 5-year relative survival is 98 % in [Sweden](#) and 98.8 % in [Norway](#).

Treatment protocols and studies are now primarily focused on minimizing risks of serious late effects without impairing treatment outcomes and developing treatment to increase survival for those with the poorest prognosis where new treatment concepts are evaluated.

5 Diagnosis and Clinical Staging

5.1 Diagnosis

See Flowchart chapter [3](#).

5.1.1 Procedures before orchiectomy

- Ultrasound examination of both testicles with volume measurements in ml
- General physical examination
- Serum levels of AFP, β -hCG, LDH
- Serum levels of PLAP, optional
- Serum levels of LH, FSH, testosterone and SHBG
- CT scan chest and abdomen-pelvis
- Patients should be offered [pre-orchiectomy sperm count with cryopreservation](#)
- Patients should be offered a testicular prosthesis
- History of prior testicular disorder and hereditary information

5.1.2 Clinical examination of the testes

Testicular cancer usually presents as a painless, unilateral intrascrotal mass and is in the majority of cases diagnosed by palpation. Approximately 10 % of patients will present with clinical symptoms mimicking epididymitis. Ultrasound of both testicles should be performed, and exploration should be performed in all cases when clinical or ultrasound investigations cannot exclude a tumour.

5.1.3 Serum tumour markers

In nonseminoma about 40% of patients with CS I, and up to 85% of metastatic patients have an elevation of either one or both serum tumour markers AFP and β -hCG (3). In contrast seminoma patients often lack elevated tumour markers. Marker concentration is dependent on histological subtype and tumour burden. An elevated level of LDH occurs in testicular cancer patients and is also used as a prognostic marker.

The determination of AFP and β -hCG is used in order to:

- Identify occult spread (radiologically CSI)
- Identify nonseminomas that morphologically are seminoma
- Assess prognostic risk group classification in metastatic nonseminoma
- Diagnose germ cell tumours in mediastinal or retroperitoneal masses
- Evaluate treatment effect
- Identify relapse

5.1.3.1 Beta-human chorionic gonadotropin (β -hCG)

β -hCG is slightly/moderately elevated depending on tumour volume in 40-60% of the patients with nonseminoma and 20–50 % of the patients with seminoma. High levels of β -hCG (>200) should raise

the suspicion of nonseminomatous germ cell components i.e. choriocarcinoma and the specimen should be re-examined. The presence of necrosis in the primary tumour might explain why nonseminomatous elements are found in the metastasis but not in the primary tumour.

The serum half-life of β -hCG should be ≤ 3 days. However, the rate of reduction in the concentration of β -hCG following chemotherapy may follow a more complex pattern, with longer apparent half-life during later stages of chemotherapy, even in patients treated successfully (4).

Cross reactivity with the beta unit of the LH might occur resulting in a false positive test.

Furthermore, hypogonadism can induce LH as well as β -hCG production by the pituitary gland. Short course of testosterone replacement therapy suppresses pituitary LH and β -hCG secretion, allowing for measure of β -hCG of germ cell origin.

β -hCG can also be produced by tumours of other origin such as liver, pancreas, stomach, kidney and bladder cancer (5).

5.1.3.2 Alpha-fetoprotein (AFP)

In germ cell tumours AFP is secreted by embryonic cell carcinoma and yolk sac tumour. AFP is by definition not consistent with a seminoma diagnosis. The detection of significantly elevated levels of AFP in a patient with seminoma implies that the tumour specimen should be re-examined with respect to nonseminomatous elements. Even if these are not found, the tumour should be considered and treated as a nonseminoma! One should be aware that reparative and infectious/viral processes of the liver as well as cirrhosis and trauma also may induce an increase in AFP, sometimes as high as > 500 ng/ml. Rarely patients constitutionally have an AFP level moderately elevated above the normal range. A modest and stable elevated AFP level might thus be compatible with a seminoma diagnosis. The serum half-life of AFP should be ≤ 7 days.

AFP can also be elevated in hepatocellular carcinoma as well as pancreatic cancer, gastric, colorectal and bronchial cancer.

5.1.3.3 Lactate dehydrogenase (LDH)

LDH is a cytoplasmic enzyme in all living cells and elevated values are seen in all kinds of tissue destruction and cell death. Total serum LDH level is elevated in about 40-60 % of patients with germ cell testicular cancer. Typically, it is the elevation of LDH isoenzyme number 1 that is seen. LDH elevation is taken into consideration in the prognostic risk group classification for nonseminoma but is less specific for germ cell tumours than AFP or β -hCG. LDH has recently been found to impact prognosis also in metastatic seminoma. Insignificant elevated levels of LDH are commonly seen during follow-up.

5.1.3.4 Placental alkaline phosphatase (PLAP)

PLAP is elevated in 50 % of the patients with seminoma but is only analysed in a few laboratories (6). It may also be elevated in nonseminoma tumours containing seminoma components. The use of this marker is optional. It could specifically be considered in evaluating unclear lesions, in stage IIA or post chemotherapy residual disease. It may be the only elevated marker in metastatic disease and can thus be useful during follow-up of such patients. PLAP may be falsely elevated in smokers.

5.1.3.5 MicroRNA (MIR371-374)

The standard tumour markers (β -hCG, AFP, LD) are elevated in less than 60% of all testicular cancer patients, dependent upon histology and stage. New markers are therefore warranted. MicroRNAs are presently under evaluation as new biomarkers (7).

5.2 Fertility measures and hormonal analyses

Cryopreservation of sperm should be offered before orchiectomy, up to 55 years of age. There may be regional variations in regard to age limits. If not performed before orchiectomy it should always be offered before start of any therapy although adjuvant chemotherapy most probably has no long-lasting detrimental effect on spermatogenesis (8, 9). Patients receiving multiple cycles of chemotherapy, radiotherapy or retroperitoneal lymph node dissection (RPLND) are at risk of subfertility/ infertility.

Sex hormones (LH/FSH, testosterone and SHBG) should be analysed before and after orchiectomy and during follow up. Serum for the hormone analyses should preferentially be sampled in the morning or at least before noon (due to their circadian variations).

Contraception should be used for six months after treatment with chemotherapy or radiotherapy.

5.3 Inguinal exploration, orchiectomy and biopsy

An incision, similar to that performed in patients with inguinal hernia, is done. The anterior wall of the inguinal canal is divided, and the vas and spermatic vessels are dissected free at the internal opening of the inguinal canal. In most cases the diagnosis is certain, and the spermatic vessels and the vas are divided immediately. The testis and epididymis with their surrounding tunica vaginalis are pushed out of the scrotum and dissected free from the scrotal wall. The vas and the spermatic vessels are ligated and divided separately at anulus internus. The spermatic vein should be marked with a non-absorbable suture to facilitate a later RPLND. The urologist should not incise the specimen.

If any doubt of the diagnosis, the spermatic cord is clamped before mobilization and inspection of the testis. In some case the tunica albuginea of the testis is incised, and a frozen section is sent for histology. If the result of the frozen section is a benign condition (for example adenomatoid tumour or epidermoid cyst), it is recommended to perform a local resection instead of an orchiectomy.

It is recommended to offer every patient a testicular prosthesis before orchiectomy (10). Though surgical complications are rare, a significant number of patients will have complaints about the size, shape, position or consistence of the prosthesis (11). Preoperative counselling is paramount. If the patient would like to have a testicular prosthesis, it is recommended to close the opening to the scrotum with an absorbable tobacco-pouch suture above the prosthesis and/or fixate the prosthesis, to prevent migration.

5.3.1 Hemiscrotectomy

In the rare cases where tumour invades the scrotal wall, a hemiscrotectomy should be performed. If the tumour has been incised with risk of tumour seeding, a hemiscrotectomy may be considered (12-14).

5.3.2 Organ-sparing surgery

Organ-sparing surgery in testicular cancer is only indicated in a few selected cases and is not recommended in the presence of a normal contralateral testis. If the radiologists strongly suggest a suspicious benign tumour (ex. epidermoid cyst), resection of the tumour may be considered, even in the case of normal contralateral testicle. However, in these patients one should proceed to radical orchiectomy if frozen section analysis reveals a malignant tumour. For small incidental tumours detected by ultrasound, see [5.5](#).

Indications for organ-sparing surgery are tumours in both testes or tumour in a solitary testis. The aim is to preserve some endocrine function. The tumour volume should be less than 30 % of the testicular volume. The tumour should be resected with a rim of surrounding tissue. Multiple biopsies of the surgical bed should be taken as well as one or two random biopsies to rule out widespread germ cell neoplasia in situ (GCNIS). The necessity of clamping the blood supply and cooling the testicle during the procedure has recently been questioned. Being an infrequently performed procedure, it should be performed at centres with some experience in handling these patients. All patients should be offered adjuvant local radiotherapy because of the high risk (> 85 %) of concomitant GCNIS. The radiation therapy may be delayed with the same precautions as mentioned in [5.4](#). (15-17).

5.3.3 Biopsy of the contralateral testis

Patients with risk factors are recommended a contralateral biopsy to detect possible GCNIS, and this is done at the time of orchiectomy.

The risk factors are in addition to a contralateral germ cell tumour:

- Cryptorchidism
- History of infertility or sperm count $\leq 10\text{mill/ml}$
- Atrophic testicle ($<12\text{ml}$)
- Heredity
- Microlithiasis

In patients over 40 years without any risk factors, the risk of GCNIS is very low, and biopsy is not recommended.

A double-biopsy procedure yields an increase in sensitivity as compared to a single-biopsy procedure (5, 18) and is recommended. Surgical complications are reported to occur in 2-3 % of the patients and are mostly managed conservatively (19).

The double biopsy is best done as follows:

The testis should be held firmly, and a small scrotal incision is made at the cranial pole. Then the tunica vaginalis should be opened. The tunica albuginea should be incised at the cranial pole,

laterally (to spare the central vessel of the testis). The first biopsy is taken at this site. Snip off a tuft of tubules cleanly with fine sharp scissors (3-4 mm specimen). The small incision of the tunica should then be closed with a running suture. Then the second incision in the lower pole to the tunica albuginea is performed to excise another specimen for histology. Again, refrain from the midline to spare the main vessel. Close the incision in the tunica and skin separately.

In an atrophic testicle a single biopsy is sufficient.

While performing the biopsies, careful handling and placement in fixative is important to prevent mechanical damage. The evaluation of GCNIS in testicular biopsies requires experience and the pathological examination of the biopsies should include immunohistochemistry.

5.3.4 Microlithiasis

Testicular microlithiasis as sole risk factor is not an indication for biopsy (20).

In men seeking care for infertility and presenting with testicular atrophy (one or both testes below 12 ml) and/or a history of cryptorchidism, testicular biopsy is indicated if testicular microlithiasis is found.

5.4 Management of GCNIS

Testicular irradiation will lead to eradication of all germ cells and permanent sterility. Therefore, if the patient has a wish of future fertility the following precautions should be taken:

- Cryopreservation of sperms prior to irradiation is recommended
- In case of azoospermia (no sperms in the ejaculate) and a strong wish of preservation of fertility, multiple testicular biopsies, and if intratesticular elongated spermatids are found, subsequent cryopreservation is an option to be discussed with the patient

1) Unilateral testicular germ cell cancer (TGCC) and GCNIS in the contralateral testis:

- a) If the patient has a partner, immediate wish of having a child and significant sperm output (this issue needs to be discussed with an andrologist / fertility specialist), some months to a few years of surveillance, while the couple is trying to obtain pregnancy, can be recommended. During this period ultrasound should be performed every 6th month and the patient should be encouraged to self-examination.
- b) In patients not receiving chemotherapy: GCNIS can be eradicated by local irradiation given as 9 daily doses of 2 Gy (total dose – 18 Gy). It has been suggested that the irradiation dose should be increased to 20 Gy. However, so far, there is no evidence to show that 20 Gy implies a lower risk of therapy failure but seems to be associated with a higher risk of androgen deficiency (21). Although some of the men subsequently develop androgen insufficiency; in more than 50% androgen replacement is not required, at least the first years after local irradiation.

- c) In patients receiving chemotherapy: Platinum-containing chemotherapy may eradicate GCNIS. Patients with GCNIS may develop invasive cancer in spite of chemotherapy (22). The safest alternative is to give local irradiation as indicated under a). An alternative is to repeat the biopsy, 1–2 years after completion of chemotherapy, and perform ultrasound every 6 months until biopsy. If GCNIS cells are present, irradiation should be offered. However, it should be kept in mind that following chemotherapeutic treatment the GCNIS cells may be reduced in number without being completely eradicated. A double biopsy is therefore recommended as the sensitivity of a single testicular biopsy is, expected to be lower than the figures given above and the risk of late contralateral TGCC exists. Even if the re-biopsy is negative, testicular ultrasound should be performed once yearly during the follow-up;
- 2) Patients with extragonadal disease and GCNIS in one testicle: Orchiectomy of the affected testicle is recommended.
 - a) Bilateral GCNIS: Irradiation as indicated under 1b.
 - b) Unilateral GCNIS and no malignancy in the other testis: Orchiectomy.

The procedure for radiotherapy of GCNIS can be found [here](#).

5.4.1 Guidelines for follow-up after testicular irradiation for GCNIS

- Control testicular double biopsy should be done 24 months after irradiation and should disclose Sertoli-cell only pattern. Presence of germ cells indicates failure of the radiotherapy.
- Serum levels of testosterone, SHBG, LH, and FSH should be checked prior to the radiation therapy, 6 and 12 months after. Subsequently the tests should be repeated with 12–24 months interval.
- Testicular ultrasound should be performed when follow-up is completed at 5 or 10 years.

5.5 Incidental finding of small lesions in testis

With increasing application of high frequency scrotal ultrasound imaging, incidental finding of small-volume masses of the testicle has emerged as a problem in clinical practice. In patients with normal tumour markers, a significant fraction of these small (< 1 cm) asymptomatic lesions are benign. Very small tumours (≤ 5 mm) may undergo surveillance with ultrasound imaging after 2 months. When histopathology of the lesion is regarded as necessary due to growth, this should be obtained by enucleation of the tumour with frozen section analysis. Percutaneous needle biopsy should not be performed. The specificity of frozen section analysis in this situation is > 90%. If frozen section reveals malignancy, radical orchiectomy is recommended.

The enucleation biopsy may be assisted by ultrasound guidance by an experienced radiologist.

5.6 Pathological examination of the testis

See the [ICCR guideline for neoplasia of the testis](#) and [KVASt](#).

Macroscopic features and sampling:

- Side, testis size, tumour size and the macroscopic features of the tumour, such as macroscopic involvement of epididymis, spermatic cord and tunica vaginalis.
- Sampling: 1 cm² section for every cm of maximal tumour diameter, including normal macroscopic parenchyma (if present), tunica albuginea and epididymis selection of suspected areas. At least one proximal and one distal section of spermatic cord, plus any suspected area.

Microscopic features and diagnosis:

- Histological type according to the 2016 WHO classification. Only pure seminoma tumour cells are classified as a seminoma. Spermatocytic tumour is not included in this protocol.
- Presence or absence of tumour vascular invasion, stromal rete testis invasion, tunica albuginea, tunica vaginalis, epididymis or spermatic cord invasion.
- Presence or absence of intratubular germ cell neoplasia in non-tumour parenchyma.
- pT category according to TNM 8th version.
- Immunohistochemical evaluation should be used in case of diagnostic difficulties.

5.7 Staging Investigations

Tests to be performed following orchiectomy - clinical staging procedures

- Serum levels of AFP, β -hCG, LDH, (PLAP optional).
- Serum levels of LH, FSH, testosterone and SHBG.
- CT of chest, abdomen and pelvis with intravenous and oral contrast, if not done before orchiectomy. If there is clinical indication of advanced metastatic disease, the CT should be done before orchiectomy.
- MRI of the brain is required in patients with clinical symptoms or signs indicating brain metastases, if β -hCG is > 50 000, massive pulmonary metastases as well as in patients with non-pulmonary visceral metastases.
- MRI of the spine and pelvis is required in patients with clinical symptoms or signs of bone metastases and in patients with non-pulmonary visceral metastases.
- Other investigations may be indicated on an individual basis.
- Follow tumour markers weekly until nadir/normalisation according to half-life decay. In presumed stage I patients, or where in doubt of stage, continue until the second staging is completed.
- A second staging with CT and tumour markers, as above should be done for all presumed stage I patients with nonseminoma 6-8 weeks from orchiectomy.

Any clear deviation from the half-life plots indicates metastatic disease, thus ending the observation period.

PLAP may also be analysed in seminoma and surveyed and is associated with metastatic disease when elevated in a non-smoker.

If there is evidence of metastatic disease, the patient should be referred immediately to an oncology department for further evaluation and treatment.

Prognostic group classification in metastatic disease should be performed immediately prior to treatment.

5.7.1 Patients with slightly enlarged paraaortic lymph nodes/suspected metastases in presumed clinical stage IIA marker negative

Slightly enlarged retroperitoneal lymph nodes <2 cm in patients without elevated tumour markers offer a diagnostic problem. These lymph nodes may be benign or represent metastases. An observation period of 8 weeks (seminoma)/ 6-8 weeks (nonseminoma) with a second staging is recommended unless a biopsy verifies metastatic disease. See [8.2.2](#) and [8.3.3.1](#).

Serum levels of β -hCG and AFP must be monitored every other week during this observation interval.

Positron emission tomography (PET)-CT may add information in seminoma but may not be reliable in small lymph nodes. Even if a PET-CT is positive, a biopsy can be considered if feasible.

In patients with low stage metastatic seminoma, preoperative PET-CT is mandatory for all patients planned for surgery.

If the stage still is equivocal after the 6-8 weeks observation period, further observation is warranted, or a laparoscopic lymph node biopsy/resection can be an option. If a biopsy is not feasible a unilateral RPLND can be considered and discussed on a regional or national MDT.

Chemotherapy (or radiotherapy) should not be initiated unless metastatic disease is unequivocal, (e.g. growth or positive biopsy).

6 Imaging

6.1 Diagnosis and Staging

Ultrasound is used to confirm an intratesticular mass, microcalcifications, presence of synchronous tumours and to measure volume of both testicles. Other imaging procedures of the testes should not routinely be performed.

Computed tomography (CT) of the thorax, abdomen, and pelvis is required as part of the initial staging procedure. Oral and intravenous contrast media is mandatory at baseline. If solitary or multiple small (<5 mm) pulmonary nodules are found, the decision whether to biopsy or follow-up must be taken individually for each patient (23).

When interpreting retroperitoneal lymph nodes on CT, irrespective of size criteria for metastases used, the limited sensitivity and specificity for characterisation of lymph nodes should be considered in the clinical management (24, 25). Therefore, the differentiation between clinical stages I and IIA is unreliable, if β -hCG and AFP are normal. A detailed description of the location, number, and size of lymph nodes, preferably in three dimensions, but at least with measures of the two longest perpendicular axial diameters should be provided in the radiology report (26, 27).

MRI of the abdomen and pelvis is associated with similar limitations in sensitivity and specificity in the staging situation (25, 28), and has not proven to provide additional information in this disease. MRI is the preferred option in patients in whom intravenous contrast media cannot be given.

On the basis of available data, FDG-PET has not demonstrated to improve sensitivity of staging of testicular cancer compared with CT scanning alone (29-32). In this current prospective treatment protocol PET scans are recommended before treatment in low volume metastatic seminoma, and before RPLND in CS IIA marker negative nonseminoma.

MRI is the preferred method to investigate the presence of brain or bone metastases. See [Chapter 5.7](#) for indications. Other investigations should be performed according to symptoms.

6.2 Treatment Evaluation

The standard modality for response evaluation is CT of the thorax, abdomen and pelvis. MRI should be used in patients with contraindications to CT. A detailed description of the location, number, and change of size of metastatic sites with measures of at least the two longest perpendicular axial diameters should be provided in the radiology report (26).

Image guided response evaluation during treatment for metastatic disease is a challenge. Response evaluation should always be performed in a hospital with a multidisciplinary team consisting of radiologists, oncologists and surgeons available, all with experience in treating patients with germ cell tumours.

PET-CT during treatment has currently no proven role outside clinical trials/prospective protocols.

For the use of PET-CT with regard to handling of postchemotherapy tumour masses in seminoma, see [8.2.5](#).

6.3 Follow-up

It is desirable to reduce the total radiation dose from repeated diagnostic imaging procedures to the patient without compromising the quality of follow-up. This is of particular concern in patients below 35 years at diagnosis. MRI of the abdominal and pelvic lymph node areas is the preferred method to investigate the retroperitoneum during follow-up.

Ultrasonography may also be performed if the necessary expertise is available. However, ultrasonography of the retroperitoneum is usually less sensitive to detect retroperitoneal lymph nodes than MRI or CT. Therefore, if there is any ambiguity, an MRI examination must be performed. Since CT is associated with undesirable total radiation dose to young patients if repeated many times during follow up it is advisable to perform MRI at least once yearly if ultrasound is used in the follow-up.

MRI should be performed according to the principles of the [imaging protocol](#). A dialogue with the responsible radiologist is necessary to make sure that the principles of the protocol and the reasons for the follow-up are fully understood.

7 Clinical Stage I

7.1 Seminoma

7.1.1 Background Seminoma Clinical Stage I

Seminoma constitutes close to 60 % of patients with testicular cancer. Of these, 85 % present with clinical stage I, making CS I seminoma the most common form of testicular cancer (28).

The optimal management of CS I seminoma remains an area of debate. In the European Germ cell Cancer Consensus Group (EGCCCG) there was no consensus on recommended treatment to patients with CS I seminoma (33). In the current [ESMO](#) and [EAU](#) guidelines both surveillance and carboplatin are recommended treatment options, but adjuvant therapy was not recommended in low-risk patients. The risks and benefits of different approaches must be discussed with the patient with respect to the different advantages and disadvantages, in both the short and long term. Non-compliance with surveillance strategies remain an area of concern.

7.1.2 The SWENOTECA experience Seminoma CS I

The SWENOTECA V protocol (2000-2006) was a Swedish-Norwegian program including patients with all stages of seminoma. Patients with CS I had the option to choose either adjuvant radiotherapy 25.2Gy/14 fractions or surveillance. In 2004 when the results of the randomised study between adjuvant carboplatin and radiotherapy were acknowledged, the options were altered to include adjuvant carboplatin (34). In the SWENOTECA VII protocol (2007-2010), the treatment in CS I was adjusted to the possible prognostic risk factors, i.e. size of primary tumour and stromal invasion in the rete testis (35). Patients with 0-1 risk factors were recommended surveillance but could choose one course of adjuvant carboplatin (AUC7), while patients with two risk factors were recommended one course of adjuvant carboplatin but could choose surveillance. An analysis of CS I patients included in SWENOTECA VII until 2010 and patients from SWENOTECA V treated with adjuvant carboplatin was performed in 2014. In total 1064 patients were included in the analysis, 669 patients received adjuvant carboplatin, 339 were managed by surveillance and four patients received other adjuvant treatments. Stromal invasion of the rete testis and tumour size > 4 cm were both confirmed as independent risk factors predicting relapse in a multivariate analysis.

7.1.3 Surveillance

Based on large, unselected patient series on surveillance we know that 85 % of patients in CSI are cured by orchiectomy alone (34, 36, 37). The overall survival in these patient series approach 100 %, and surveillance is an attractive strategy. There have been several attempts to identify possible prognostic factor for relapse. A seminal article published in 2002, pooled 638 patients from four centres (35). This retrospective study identified tumour size > 4 cm and stromal rete testis invasion as independent risk factors for relapse. However, an unpublished validation study from the same group could not confirm the prognostic value of these proposed risk factors (38). The results from SWENOTECA V, published in 2011, also failed to identify any prognostic factor for relapse (34). Results from a recent Spanish risk-adapted protocol give some indications that patients without any of the proposed risk factors have a very low risk of relapse (39). Published results from SWENOTECA VII, confirmed a low risk of relapse in this group of patients, with a 4.0 % relapse rate. Both invasion of the rete testis and tumour size > 4cm were found to be risk factors predicting relapse. In

SWENOTECA VII the relapse rate in patients with 1-2 risk factors and managed with surveillance was 15.5 % (40).

7.1.4 Adjuvant Carboplatin

In 2005 results from a large randomised trial of one cycle of adjuvant carboplatin versus adjuvant radiotherapy was reported (41). The long-term mature data were presented in 2011 (42). The study included 1447 patients with a median follow-up of 6.5 years. 573 patients received one cycle of carboplatin (AUC 7). The relapse rate following one course of adjuvant carboplatin was 5.3 %. Combined results from SWENOTECA V and VII, where 669 patients received one course of carboplatin, found a relapse rate of 6.2 % after a median follow-up of 5.2 years (34, 40, 43). Stromal invasion of rete testis or tumour size > 4 cm result in a higher risk of relapse, 9.4 %. Due to these results the ABC-study was initiated by SWENOTECA in 2015, randomizing patients with 1-2 risk factors to BEP x 1 or standard adjuvant treatment with Carboplatin. For details regarding the study see www.swenoteca.org.

Carboplatin has a steep dose-response interval. Inferior outcomes, with more relapses have been reported when a lower dose than AUC 7 has been given. AUC 7 should always be calculated from uncorrected GFR, measured by iohexol- or Cr-EDTA clearance. eGFR based on both Cystatin-C and creatinine may also be used, except for patients on cortisone medication or cachectic patients. See www.egfr.se for further information and to calculate the uncorrected/absolute GFR to be used for the dosing of carboplatin.

Several non-randomised trials have explored two courses of adjuvant carboplatin (AUC 7 or 400 mg/m²), with a reported relapse rate of about 2 % (39, 44-46).

If adjuvant chemotherapy is given, it should be started as soon as possible after the definitive clinical staging.

Dosage schedule of [carboplatin](#).

7.1.5 Adjuvant Radiotherapy

Until recently, standard adjuvant treatment of CSI seminoma has been radiotherapy. Based on large randomised studies conducted by the MRC, we know that 20 Gy given to a para-aortic field results in a relapse rate of about 4 % (42). In SWENOTECA V the relapse rate following 25.2 Gy to a para-aortic and ipsilateral iliac lymph nodes was 0.8 % (34). Due to the increased risk of cardiovascular disease and secondary cancers following radiotherapy, radiotherapy is no longer recommended as a standard adjuvant treatment.

Radiotherapy may still be an option in those who are not eligible for adjuvant chemotherapy or surveillance.

7.1.6 Treatment Recommendations Seminoma Clinical Stage I

Both invasion of the rete testis and tumour size > 4 cm predict relapse following surveillance or adjuvant carboplatin (AUC7). Patients without any of these proposed risk factors have a low risk of relapse. SWENOTECA propose a modified risk-adapted strategy for adjuvant treatment in CSI seminoma.

A risk adapted strategy is recommended in CSI seminoma. Thorough oral and written information should be presented to the patient taking patient autonomy in consideration

Patients with a tumour ≤ 4 cm and no stromal invasion of the rete testis are recommended surveillance

Patients with a tumour > 4 cm and/or stromal invasion of rete testis are recommended treatment with one course of adjuvant carboplatin AUC 7. Options are participation in the ABC-study (randomisation between 1 BEP and 1 Carboplatin, see protocol) or surveillance

Adjuvant radiotherapy is only recommended for those who are not suitable for adjuvant chemotherapy or surveillance. See chapter 16 for details

7.2 Nonseminoma

7.2.1 Background Nonseminoma Clinical stage I

About 60% of the nonseminoma patients are in clinical stage I. In the EGCCCG there was consensus on recommending treatment with adjuvant BEP x 1 to high-risk patients (presence of lymphovascular invasion) and surveillance to low-risk patients (33). [ESMO](#) and [EAU](#) guidelines recommend surveillance and adjuvant BEP as treatment options based upon the presence of risk factors. The risks and benefits of each strategy should be discussed with patients in respect to its immediate and long-term impact, also for low-risk patients. Non-compliance with surveillance strategies remain an area of concern. RPLND is an option in specific situations.

The risk of occult metastatic disease in CSI NSGCT is highly dependent on the presence of lymphovascular invasion (LVI) in the tumour (47, 48). LVI is present in about one-third of the tumours. In patients with tumours with presence of LVI, the risk of recurrence is about 50%, and in those without LVI, 15–20% (49, 50). Recurrences occur most commonly in the retroperitoneum, with the majority of the recurrences diagnosed within 2 years after orchiectomy (51, 52). Management options for CSI NSGCT are surveillance, retroperitoneal lymph node dissection (RPLND), and adjuvant chemotherapy. The decision regarding treatment should always be based on a thorough discussion with the patient on the pros and cons of each strategy. Written patient information should also be provided

7.2.2 The SWENOTECA experience Nonseminoma CS I

The SWENOTECA has published population-based data on risk-adapted treatment in CS I NSGCT where 745 patients were included during the period of 1998-2005. The aim was to reduce the risk of

relapse and thereby reducing the need for later salvage chemotherapy while maintaining high cure rates. LVI+ patients were treated with one course of BEP and LVI- patients had the choice between surveillance or one course of BEP. At a median follow-up of 4.7 years one course of BEP reduced the relapse rate by 90% in both LVI+ and LVI- patients resulting in a relapse rate of 3.2% and 1.4%, respectively. An update was published 2014 including 517 patients treated with one course of BEP. With a median follow-up of 8 years the results were confirmed, with no relapses after 3.3 years and 100% cause-specific survival (52).

7.2.3 Surveillance

Some centres advocate surveillance for all CSI NSGCT, accordingly no patient will be treated unnecessarily; however, 50% of those with LVI and 15% of the patients without LVI will later need salvage treatment (36, 49, 50, 53, 54). Compliance to follow-up schedules is of paramount importance if surveillance is applied.

7.2.4 Adjuvant BEP

One course of adjuvant BEP reduced the risk of relapse by 90–95% in all patients (52).

7.2.5 Primary Nerve sparing Retroperitoneal Lymph Node dissection (RPLND)

Primary nerve sparing bilateral RPLND – is the standard treatment in patients with CS I with malignant somatic transformations in the testicular tumour(27). Treatment after RPLND has to be considered according to pathological findings. Primary unilateral RPLND may be discussed as an alternative to surveillance or adjuvant chemotherapy in patients not willing to undergo either of these treatment strategies.

7.2.6 Treatment Recommendations Nonseminoma Clinical Stage I

A risk adapted strategy is recommended in CSI nonseminoma. Thorough oral and written information should be presented to the patient taking patient autonomy in consideration

High-risk patients, LVI+ (lymphovascular invasion), are recommended one cycle of adjuvant BEP

Patients with LVI-, may choose the equal options of surveillance or adjuvant BEP

Exceptions see below

Patients with malignant somatic transformation in the testicular tumour

- Primary bilateral nerve sparing RPLND is the standard treatment of patients with CS I with malignant somatic transformation (27). Treatment after RPLND has to be considered in regard to pathological findings (55).

Postpubertal teratoma only in the testicular tumour

- Should be followed as nonseminoma stage I surveillance, and should not receive adjuvant therapy

If adjuvant chemotherapy is given, it should be started as soon as possible after the definitive clinical staging. In general, we do not recommend adjuvant therapy initiated later than twelve weeks following orchiectomy. The [BEP](#)-regimen is used. When the bleomycin is given on day 15, full blood counts for toxicity evaluation should be taken. The SWENOTECA “Behandlingsblankett” is filled in and registered in the national SWENOTECA quality registry. Registration of toxicity is especially important. The addition of G-CSF is recommended to minimize the risk of toxicity also in the adjuvant situation.

8 Metastatic Disease

8.1 General Comments Metastatic Disease

For unequivocal metastatic disease, chemotherapy should start as soon as possible after staging is completed. In widespread life-threatening poor prognosis disease, orchiectomy must not delay the initiation of curative chemotherapy.

In managing metastatic disease, the stage of the disease and the risk classification according to the International Germ Cell Cancer Collaborative Group (IGCCCG) classification impacts treatment guidelines. The original IGCCCG classification from 1997 has been updated, based on 12 135 patients treated 1990-2013 (56). The updated results support the principles of the original classification but suggest that the prognostication can be further refined.

Dose reductions and treatment delays should be avoided. G-CSF as primary prophylaxis is recommended, see [9.3](#).

Patients should be considered for thromboprophylaxis, see [9.4.1](#).

Intermediate and poor prognosis patients should always be transferred to a centre with experience in treating advanced germ cell tumours before start of treatment. In addition, all patients with abdominal metastasis over 5 cm should be discussed with a centre with experience in treating advanced germ cell tumours before start of treatment.

In case of hydronephrosis, the kidney should be relieved before initiation of chemotherapy.

The treatment of progressive disease should be discussed within the SWENOTECA network.

Treatment of metastatic disease in elderly patients must be done with great care regarding their individual tolerance.

8.2 Metastatic Seminoma

In small volume abdominal disease, unilateral retroperitoneal lymph node dissection is the preferred treatment, see [10.1](#). Optional therapy consists of chemotherapy or radiotherapy. Patients with more advanced disease are recommended treatment with cisplatin in combination with etoposide and bleomycin (BEP), substituted with etoposide and cisplatin (EP) or with additional ifosfamide (PEI) in patients with contraindications to bleomycin, see [9.1.3](#), depending on prognostic [risk group](#).

	5-year PFS (%)		5-year OS (%)	
	1997	Update 2020	1997	Update 2020
<i>Good</i>	82	89	86	95
<i>Intermediate</i>	67	79	72	88

Metastatic Seminoma: PFS and OS according to the IGCCCG classification in the original publication, to a recent IGCCCG update (4902 patients treated 1990-2013, including SWENOTECA data)

8.2.1 The SWENOTECA experience CS II-IV seminoma

In 102 patients with CS IIA/B seminoma, three patients (2.9%) relapsed. In all three, the primary treatment was radiotherapy, and one patient relapsed within the radiation field. In 73 patients treated with chemotherapy (EP/BEP) there were no relapses reported (34). All 86 (6%) patients with more advanced tumour spread (CS IIC/D, III and IV) were treated with chemotherapy initially. The 5-year cancer specific survival for all patients treated for seminoma was excellent with a survival of 99.6%, with a 5-year cancer specific survival in good prognosis metastatic seminoma of 97.2%.

The challenge is to minimise treatment and follow up without compromising the oncologic outcome for these young men and to retain fertility and quality of life. The observed survival in the intermediate prognosis group is uncertain due to the low number of patients treated, but every effort should be made to improve survival in this small group of patients.

8.2.2 Clinical Stage IIA-IIB (≤ 3 cm) Seminoma

Patients with CS IIA seminoma have a limited disease with abdominal lymph node metastases < 2 cm in largest axial diameter. Consequently, tumour markers are usually negative. To stage these patients properly see [5.7.1](#).

The standard treatment of CS IIA has been radiotherapy or chemotherapy. Radiotherapy is given to a para-aortic and ipsilateral iliac field. A target dose of 25-30 Gy results in a relapse free survival of 88-95 %, according to data in the literature (34, 57). Accumulating data on long-term morbidity following radiotherapy has brought forward chemotherapy as an alternative to radiotherapy in this group of patients, with very few relapse (34). However, chemotherapy also leads to long-term morbidity (58).

As seminoma mainly metastasizes lymphatically, primary RPLND is a compelling treatment strategy, with lower risk of long-term morbidity (8, 34, 57, 59-61).

Several groups have reported results of using RPLND as primary treatment of seminoma, and a review of the subject has recently been published (62, 63). There are known risks of RPLND, including retrograde ejaculation, infections, bleeding and chylous ascites. The procedure is standard treatment when removing remaining lesion following chemotherapy for metastatic nonseminoma, and in primary treatment of nonseminoma CS IIA Mk-. Surgery is much more complicated after chemotherapy compared to primary RPLND, where the risk of mortality is reported to close to zero (64-66). Currently, several studies include patients for primary RPLND in non-bulky metastatic seminoma, i.e CS IIA + IIB ≤ 3 cm, 1-2 metastatic lymph nodes. Data from several previous small studies have shown a relapse-rate close to zero in this group of patients, provided stage was confirmed surgically (67, 68).

Given the increasing awareness of long-term toxicities associated with chemotherapy and radiotherapy, and the known efficacy of RPLND in regional control of seminoma, it is reasonable to recommend RPLND as a first-line therapy option.

Currently we have three possible treatment alternatives in non-bulky metastatic seminoma, all with excellent cure rates; primary RPLND, chemotherapy and radiotherapy.

8.2.2.1 Primary RPLND

Primary unilateral RPLND is recommended in patients with seminoma CS IIA-IIB ≤ 3 cm with 1-2 enlarged retroperitoneal lymph nodes within the template for unilateral RPLND, see [10.1.2](#).

8.2.2.2 Preoperative FDG-PET CT

Preoperative FDG-PET CT should always be performed and will have clinical implications.

Preoperative FDG-PET-CT result Clinical implications

<i>Upstaging, i.e. more than 2 lymph nodes or > 3 cm or disease outside unilateral RPLND template</i>	Treatment according to stage and risk group
<i>Positive FDG-PET-CT within unilateral RPLND template</i>	Primary unilateral RPLND
<i>Negative FDG-PET</i>	If tumour marker (β -hCG / PLAP) positive – Primary unilateral RPLND If tumour marker (β -hCG / PLAP) negative – Biopsy if feasible, if seminoma confirmed – Primary unilateral RPLND

If the pathology report from the RPLND reveals upstaging, i.e. > 2 lymph nodes with seminoma or any lymph node with seminoma > 3 cm, 1 adjuvant cycle BEP is recommended and should be discussed at regional or national MDT.

The main possible long-term morbidity of this treatment option is [retrograde ejaculation](#). Consequently, all patients must be offered preoperative sperm-cell cryopreservation, if not already performed.

These patients should have an additional follow-up visit with radiologic assessment, two months post-surgery.

8.2.2.3 Chemotherapy

BEP x 3 is the standard chemotherapy regimen. If there are contraindications to bleomycin, see [Chapter 9.3](#), EP x 4 should be chosen.

8.2.2.4 Radiotherapy IIA/IIB

The target volume includes the para-aortic and ipsilateral iliac lymph nodes to a target dose of 30 Gy with 2.0 Gy per fraction x 15, see [Chapter 15](#). In CS IIB, additional boost to GTV of 6 Gy as simultaneous-integrated boost (SIB) should be given.

8.2.2.5 Treatment recommendations clinical stage IIA + IIB ≤ 3 cm seminoma, 1-2 metastatic lymph nodes

Surgery: Primary RPLND (+ adjuvant BEP x 1, if pathology report reveals upstaging)

Chemotherapy: BEP x 3 (bleomycin contraindicated: EP x 4)

Radiotherapy: 2.0 Gy x 15 to para-aortic and ipsilateral iliac lymph nodes. In clinical stage IIB, additional boost to GTV of 6 Gy (given as SIB)

Flowchart: [Appendix III](#)

8.2.3 Clinical stage IIB (>3 cm) - IV seminoma

In the International Germ Cell Consensus Classification, metastatic seminoma is classified as good or intermediate prognosis. Adverse prognostic factors are non-pulmonary visceral metastases.

CS IIB patients were previously treated with radiotherapy. The reported relapse rates are 9–24 %, based on small patient series (34, 57, 69, 70). The relapses after radiotherapy are predominately located outside the retroperitoneum. In the SWENOTECA patient series, 67 patients with seminoma CS IIB treated with chemotherapy had a relapse-free survival of 100% after median 5.5 years follow-up. Although there are no randomised studies comparing radiotherapy and chemotherapy in CS IIB, chemotherapy is recommended to patients with CS IIB > 3 cm, due to the high reported relapse rates with radiotherapy.

For higher stages of seminoma than CS IIB, there is international consensus on treatment with 3-4 cycles of cisplatin-based combination chemotherapy (71, 72). As patients with advanced seminoma are infrequent, there are no randomised studies comparing various cisplatin-based chemotherapy regimens for seminoma patients alone.

In the rare event of pure seminoma in the testicle and β -hCG >5000 at start of chemotherapy for metastatic disease, the patient should be treated as metastatic nonseminoma, intermediate prognosis. This recommendation is based on clinical experience, as biopsy of metastases in such cases have sometimes revealed nonseminomatous elements.

8.2.3.1 [Good prognosis](#) seminoma, clinical stage IIB (>3 cm) - IV

A randomised EORTC study comparing BEP x 3 versus EP x 4 in good prognosis seminoma, reported complete response rates at 95 % versus 87 % ($p=0.0075$) (73). Furthermore, we believe that BEP x 3 has less acute and long-term toxicities than EP x 4, due to lower cumulative cisplatin dose. The standard treatment of metastatic good prognosis seminoma is therefore BEP x 3. For patients with contraindications to bleomycin, see [9.1.3](#). EP x 4 or alternatively PEI x 3 can be given. In patients with impaired renal function, four courses of carboplatin AUC7 day 1 with standard dose etoposide day 1-

5 may be a treatment option. Single-agent carboplatin chemotherapy in standard dosage is inferior to cisplatin-based combination chemotherapy in advanced disease (74, 75); however, carboplatin AUC10 may be an option in the case of severely impaired renal function (76).

8.2.3.2 Treatment recommendations [good prognosis](#) seminoma clinical stage IIB (>3 cm) - IV

Chemotherapy: BEP x 3 (bleomycin contraindicated: EP x 4 or PEI x 3)

Flowchart: [Appendix IV](#)

Comments Good Prognosis Seminoma Clinical Stage IIB (>3 cm) – IV

- Radiologic treatment evaluation: Radiologic evaluation prior to the 3rd cycle and after completed chemotherapy.
 - In case of residual mass, see [Chapter 8.2.5](#).
- Patients with CS IIB with contraindications to chemotherapy may be treated with radiotherapy. If radiotherapy is given, a dose of 2 Gy x 15 to a total dose of 30 Gy to the para-aortic and ipsilateral iliac lymph nodes with the addition of SIB equivalent to biologically effective dose (BED) 36 Gy to the enlarged lymph nodes should be given. See [Chapter 15](#).

8.2.4 [Intermediate prognosis](#) seminoma

The standard treatment for intermediate prognosis metastatic seminoma is BEP x 4 (27). For patients with contraindications to bleomycin, see [9.1.3](#), PEI x 4 is the recommended treatment.

8.2.4.1 Treatment recommendations [intermediate prognosis](#) seminoma

Chemotherapy: BEP x 4 (bleomycin contraindicated, or brain metastasis): PEI x 4)

Flowchart: [Appendix V](#)

Comments Intermediate Prognosis Seminoma

- Radiologic evaluation prior to the 3rd cycle
 - In case of progressive disease, the patient should be discussed within the SWENOTECA network
- Radiologic treatment evaluation: After completed chemotherapy
 - In case of residual mass, see [Chapter 8.2.5](#).

8.2.5 Post-chemotherapy residual masses seminoma

Seminomatous tumours are often characterised by a slow regression rate after chemotherapy. Residual tumours mostly consist of fibrotic or necrotic tissue; however, in up to 30 % of cases residual tumours > 3 cm contained germ-cell malignancy (77-79). In post-chemotherapy seminoma residual lesions, a FDG-PET scan has a high negative predictive value (95%) and is excellent for the exclusion of active disease in lesions \geq 3 cm (80). It should not be performed earlier than 9 weeks after day 1 of the last chemotherapy course, due to the risk of false positivity. FDG-PET can contribute to the management of residual seminoma lesions, especially in terms of avoiding unnecessary additional treatment for patients with non-regressing lesions \geq 3 cm (81).

In post-chemotherapy seminoma residual lesions, a FDG-PET has a low positive predictive value (23%) for germ-cell malignancy (82). Thus, repeated FDG-PET imaging and biopsy should be considered in case of a positive FDG-PET in this situation.

- Consolidating treatment after chemotherapy (surgery or radiotherapy) should not be applied routinely
- Regressing or persisting residual mass < 3 cm: Monitor with an appropriate radiological method (MRI, CT) and serum tumour markers
- Residual mass \geq 3 cm and not regressing: FDG-PET scan is recommended, not earlier than 9 weeks from day 1 of the last chemotherapy course
- Stable residual mass and negative FDG-PET scan: Continue follow-up
- Stable residual mass and positive FDG-PET scan: Repeated FDG-PET after 6-8 weeks and biopsy before consolidating therapy is decided upon
 - Germ-cell malignancy: Surgery, if feasible
 - Germ-cell malignancy and surgery not feasible: Radiotherapy to limited fields to a total dose of 40 Gy in 2 Gy fractions

8.3 Metastatic Nonseminoma

Chemotherapy with the BEP regimen is the main first-line treatment of metastatic nonseminoma. If tumour marker decline after two cycles of chemotherapy is delayed, intensified chemotherapy is prescribed. If tumour marker progression occurs during treatment (not due to surge at day 15 in each course) the patient must be re-evaluated for sanctuary metastases in brain or bone and contralateral testicular tumour, and surgery must be considered to identify what tumour components are present to adequately change treatment accordingly.

Our general principle is that patients with retroperitoneal lymph node metastases post-chemotherapy \geq 1 cm in largest axial diameter, should be operated with RPLND. However, there might be exceptions and therefore this decision should be discussed at national/regional multidisciplinary meetings. There are certain conditions that may affect the decision, see [Chapter 10](#).

Residual tumours outside of the retroperitoneum should be resected if possible, due to discordance rates of histology between retroperitoneal and extra-retroperitoneal residual masses (83, 84). If pathological examination of the residuals from the first lung show necrosis, resection of contralateral pulmonary lesions is not mandatory (85). However, one should be aware of the possibility of discordant histology, and therefore have a low threshold for surgery in lesion showing signs of growth (86).

Several studies have shown the value of intensification of treatment based on unsatisfactory marker decline. SWENOTECA have since 1995 used unsatisfactory marker decline to initiate intensified treatment. Improved survival based on intensification in one step during initial therapy has been demonstrated (87, 88). At the end of initial treatment, slow tumour marker decline might be part of the natural tumour marker kinetics, and therefore does not indicate a need for intensification (4). We have chosen to change our intensification policy to one step intensification during initial therapy.

8.3.1 Treatment recommendations metastatic nonseminoma

Tumour markers should be measured at day 1, 5 and 15 of each course

Response evaluation of tumour markers should be performed after 2 courses, tumour marker decline should be plotted in graphs, for [β-hCG](#) and [AFP](#)

Residual tumour in retroperitoneum ≥ 1 cm post-chemotherapy: Consider surgery at national/regional multidisciplinary meeting

Surgery of other residual tumours

If germ cell cancer other than teratoma is found in post-chemotherapy residual resections, the patient should be discussed within SWENOTECA or at national multidisciplinary team meetings

8.3.2 The SWENOTECA experience CS II-IV nonseminoma

In SWENOTECA IV (1995-2010), the treatment of patients with metastatic disease was guided by tumour marker decline. All patients initially received 2 courses of BEP. Subsequent treatment was determined by rate of tumour marker decline. Patients with satisfactory marker decline continued with BEP while those with unsatisfactory decline received intensified treatment. The treatment was intensified in 2 steps: 1st step with the addition of ifosfamide and the 2nd step was high-dose chemotherapy with stem cell rescue (HDCT). Published data from SWENOTECA, included patients treated 1995 – 2003 (89). The patients with intermediate prognosis had favourable results in comparison to previously reported studies (90), and we consider the individual intensification of treatment based on delayed marker decline to be a feasible strategy to avoid over- or undertreatment of these patients. Of the patients classified as poor prognosis patients, patients with elevated tumour marker levels only had a significantly better OS compared to patients with non-pulmonary visceral metastasis (89).

In SWENOTECA VIII (2011-2020), treatment recommendations were further refined. Standard 1st line treatment was BEP, with exceptions of Bleomycin contraindications or primary CNS metastases. The initial treatment of BEP x 4 in SWENOTECA IV for good prognosis, had been changed to BEP x 3. The principles of treatment intensification remained unchanged, however intensification step 1 was changed to TIP for the poor prognosis patients with non-pulmonary visceral metastases or with a mediastinal primary extragonadal disease.

IGCCCG

	5-year PFS (%)	5-year PFS (%)	5-year OS (%)	5-year OS (%)	10-year OS (%)
	1997	Update 2020	1997	Update 2020	SW IV
Good	89	90	92	96	95
Intermediate	75	78	80	89	90
Poor	41	54	48	67	67*

Metastatic Nonseminoma: PFS and OS according to the IGCCCG classification in the original publication, to a recent IGCCCG update (9530 patients treated 1990-2013, including SWENOTECA data) and SWENOTECA IV results (treated 1995-2003).

*Extragenital tumours not included

8.3.3 [Good prognosis nonseminoma](#)

8.3.3.1 Clinical Stage IIA nonseminoma Mk-

Slightly enlarged retroperitoneal lymph nodes <2 cm in patients without elevated tumour marker levels offer a diagnostic problem. If possible, a biopsy should be performed. If biopsy is inconclusive or not feasible, further evaluation is necessary to establish “true” clinical stage.

To reduce risk of late toxicity, SWENOTECA recommends unilateral template RPLND, see [Chapter 10](#), with the addition of adjuvant BEP x 1 if germ cell cancer other than teratoma is found retroperitoneally. A preoperative FDG-PET should be performed, to gather experience in this subset of patients. Patients with pure teratoma in the testicle and low volume metastatic disease can be managed by primary RPLND (91, 92).

8.3.3.2 Treatment recommendations nonseminoma CS IIA Mk-

Second staging:

Shrinking lesion: As CS I according to lymphovascular invasion

Growing lesions with normal tumour markers and negative biopsy: RPLND. Preoperative FDG-PET. If retroperitoneal germ cell cancer (except teratoma): Adjuvant BEP x 1.

Confirmed metastatic disease i.e. rising tumour markers and/or positive biopsy (except teratoma): According to IGCCCG prognosis group

Growing lesion to > CS IIB with normal tumour markers: According to IGCCCG good prognosis group.

Pure teratoma in the testicle: Primary RPLND

Flowchart: [Appendix VI](#)

These patients should be registered as CS IIA Mk- disease according to first staging, irrespective of further findings to enable identification in the registry.

8.3.3.3 Treatment recommendations good prognosis nonseminoma, excluding CS IIA Mk-

Chemotherapy: BEP x 3 (bleomycin contraindicated: EP x 4 or PEI x 3)

Delayed decline in tumour marker after BEP x 2: Intensification with PEI x 2

If PEI given initially: Intensification with TIP x 2

Post-chemotherapy RPLND if residual tumour ≥ 1 cm, even if tumour markers elevated and declining or slightly elevated and stable (marker tail)

Surgery of other residual tumours

Flowchart: [Appendix VII](#)

Comments Good Prognosis Nonseminoma

A slightly increased but stable tumour marker is no reason to continue with a chemotherapy beyond the recommendation above, but rather to continue with resection of residual disease.

Radiological evaluation with CT of the chest, abdomen and pelvis should be performed after 2 and 3 or 4 courses (including CS Mk+ patients), to evaluate tumour regression and the need for post-chemotherapy surgery

If the patient has normal tumour markers before start of chemotherapy, and radiological regression after 2 BEP is less than 25% (tumour volume defined as the products of two perpendicular axial diameters measured on CT), surgery is recommended.

See General comments metastatic disease [Chapter 8.1](#).

8.3.4 [Intermediate prognosis nonseminoma](#)

Clinical trials on intermediate prognosis patients are sparse. The EORTC randomized phase III study on patients with intermediate prognosis germ-cell cancer, compared paclitaxel-BEP (T-BEP) to standard BEP. The study was closed prematurely due to slow accrual and OS was not statistically significant (93).

8.3.4.1 Treatment recommendations [intermediate prognosis nonseminoma](#)

The treatment of intermediate prognosis patients is the same as for patients classified as poor prognosis due to elevated tumour marker levels only. See treatment recommendation below.

8.3.5 [Poor prognosis nonseminoma](#)

Patients with non-pulmonary visceral metastases; e.g. brain, bone or liver metastases; have adverse prognosis. The SWENOTECA experience and several retrospective analyses have confirmed that non-pulmonary visceral metastases, as well as primary mediastinal GCC, are associated with a worse outcome compared to patients in poor prognosis due to elevated tumour marker levels only (94-98).

Numerous attempts have been made to improve the outcome for poor prognosis patients by intensifying the primary chemotherapy or adding high-dose chemotherapy. Many phase II trials have reported promising results with cure rates of 70-75% (99-107).

There are a few randomized trials (87, 108-111), three of which using high-dose chemotherapy with stem cell rescue in the experimental arm. None of the few randomized studies on intensified initial treatment in poor prognosis patients have shown any benefit of intensification in primary treatment compared to standard BEP.

In the study reported by Motzer, patients with delayed TM decline during initial chemotherapy had a significant benefit of high-dose chemotherapy but not patients with satisfactory TM decline. The more recent GETUG-13 trial was a randomized trial based on TM kinetics. Patients with delayed TM decline after cycle 1 BEP were randomized between 3 more cycles of BEP and intensified treatment, including oxaliplatin, paclitaxel and ifosfamide. The study confirmed the prognostic value of TM kinetics. This is the first randomized study supporting the SWENOTECA principle of taking TM kinetics into account in the treatment strategy. SWENOTECA regards the study as proof of principle, without necessarily defining the optimal intensification regimen. In SWENOTECA X, we recommend a one-step treatment intensification in patients with delayed decline of TM levels, as compared to previous two-step intensification.

8.3.5.1 [Treatment recommendations poor prognosis nonseminoma](#)

Intermediate and poor prognosis based on elevated tumour markers levels only

Chemotherapy: BEP x 4 (bleomycin contraindicated: PEI x 4)

Delayed TM decline after BEP x 2: Intensification with PEI x 3 and stem cell harvest

If PEI given primarily: Intensification with TIP x 3.

Post-chemotherapy RPLND if residual tumour ≥ 1 cm, even if tumour markers elevated and declining or slightly elevated and stable (marker tail)

Surgery of other residual tumours

Flowchart: [Appendix VIII](#)

Poor prognosis with non-pulmonary visceral metastases or mediastinal extragonadal disease

Chemotherapy: BEP x 4

Brain metastases, concerns about lung toxicity or contraindication to bleomycin: PEI x 4

Delayed tumour markers decline after BEP x 2: Intensification with TIP x 1, stem cell harvest and 2 high-dose Carboplatin Etoposide with autologous stem cell rescue

Post-chemotherapy RPLND if residual tumour ≥ 1 cm, even if tumour markers elevated and declining or slightly elevated and stable (marker tail)

Surgery of other residual tumours

Flowchart: [Appendix IX](#)

8.3.5.2 Comments to the treatment of [poor prognosis](#) nonseminoma

- The poor prognosis patients represent a small proportion of metastatic NSGCT, about 15%, of which approximately 60 % have non-pulmonary visceral metastases and 40 % are poor prognosis due to elevated TM levels only. They require treatment at centres with extensive experience in advanced metastatic germ cell cancer, and complex treatment decisions are made after discussion within the SWENOTECA network as the clinical presentation is variable and this care program cannot cover all situations.
- Some patients are in a serious condition when diagnosed, e.g. respiratory distress due to extensive lung metastases, and the start of chemotherapy should not be delayed by orchiectomy, if the diagnosis is unequivocal. Orchiectomy must be performed later without delaying systemic therapy.
- When massive pulmonary or brain metastases are present, especially in patients with choriocarcinoma, pulmonary or cerebral bleeding might occur during initial treatment and the treatment centre should be prepared to handle the situation. Patients may have to be treated at the intensive care unit.
- Tumour lysis syndrome might occur (very rarely) and the treating centre should be prepared for this and consider prophylaxis in patients with large tumour burden.
- Patients who initially are considered unfit for start of full dose chemotherapy, can be treated with an initial 3-day regimen, followed by a full-dose cycle 2 at day 15.
- Plans for possible stem cell harvest and high dose chemotherapy should be made as early as feasible, to reduce the risk of treatment delay.
- During the first 10-15 days after start of chemotherapy TM might increase (= surge). If this TM increase is not recognized, the TM decline will falsely be considered delayed. Therefore, the calculation of TM decline should be based on the TM levels on day 14/15 of the first BEP cycle and days 1, 5 and 14/15 of the second BEP cycle.
- In some patients, mostly in those with a very high TM level before chemotherapy (β -hCG $>100\,000$ IU/L, AFP $>50\,000$ ug/L), the rate of TM decline can be satisfactory after the initial 2 or 3 chemotherapy courses, but the TM decline rate slows down after the 3rd or 4th course to remain slightly increased, often around 30-50, and only slowly decreasing. This

phenomenon (a marker tail), should not be regarded as treatment failure. If in doubt, discuss within the SWENOTECA network.

- Patients with viable germ cell cancer in post-chemotherapy residual resection should be discussed within the SWENOTECA network regarding further surgery and/or chemotherapy. Efforts should always be made to achieve complete resection of residual masses (112).
- See General comments metastatic disease [8.1](#).

8.4 Brain metastases

Brain metastases have been reported in 1-2% of testicular cancer patients and approximately 10% of patients with advanced metastatic disease (113-115). Prospective clinical trials are lacking, data are from retrospective series. Primary cerebral germ cell cancers are not included in this program.

Multimodal treatment strategies should be considered in patients with brain metastases, including chemotherapy, possibly high dose treatment, plus local therapy with radiotherapy or surgery. The sequencing of modalities is not predetermined and may vary according to symptoms, tumour localization, multiplicity and size, aim of treatment i.e. curative or palliative intention. If the brain metastasis is resectable, and a short delay of start of chemotherapy is possible, consider primary brain surgery (116).

In general, chemotherapy is the initial therapy, as the majority of these patients also have extracerebral metastases. Chemotherapy containing ifosfamide has been recommended due to better CNS penetration (117). If CR on primary chemotherapy, consolidation is not needed (97). In case of progressive CNS metastases during chemotherapy, immediate surgery or radiotherapy should be considered. After chemotherapy, if resected residuals in the brain contain germ cell cancer other than teratoma, further therapy should be discussed in the SWENOTECA network.

In brain metastases at relapse, HDCT may improve survival (97).

Radiotherapy can be delivered as whole brain irradiation (WBRT) or focally with stereotactic irradiation (SRT). The optimal regimen is unknown. SRT are recommended with few (max 4) and smaller metastases (118). To manage micro-metastases, WBRT may be superior to SRT. BED > 50 Gy is recommended if WBRT is decided upon: 1.8 Gy per fraction in 22 fractions to a total dose of 39.6 Gy with simultaneous integrated tumour boost with 2.45 Gy per fraction in 22 fractions to a total dose of 53.9 Gy for germ cell brain metastases.

Multimodal treatment with chemotherapy and whole brain radiotherapy may cause progressive multifocal leukoencephalopathy (119).

In patients receiving WBRT cognitive long-term toxicity is expected. Treatment with memantine may prevent cognitive dysfunction(120)

8.4.1 Treatment recommendations brain metastases

Brain metastasis at diagnosis, see Flowchart: [Appendix XI](#)

First-line chemotherapy: PEI regimen

Brain metastasis at relapse, see Flowchart: [Appendix XII](#)

8.5 Bone metastases

Primary bone metastases are rare, in SWENOTECA IV only 3/94 poor risk patients had reported bone involvement (89). Prognosis is dismal for bone metastases in nonseminoma, with reported 2-year PFS and OS of only 24% and 36%, respectively (121). The role of local treatment following optimal systemic treatment remains unclear. When feasible, histological investigation of post-chemotherapy bone metastases should be considered; bone resection is a treatment option if teratoma is found (122). The role of additional radiotherapy is not clear (95). Also, local therapy such as vertebroplasty and thermal ablation (123) are possible treatment options. These patients should be discussed in the SWENOTECA network.

9 Chemotherapy

9.1 Conventional dose chemotherapy

Chemotherapy should be given without dose reductions at 21-d intervals. Dose reductions are highly discouraged. Postponing treatment, maximum 3 days, should only rarely be done. Chemotherapy is dosed according to body surface area (124), except for carboplatin, bleomycin and high-dose chemotherapy.

9.1.1 Cisplatin

To prevent cisplatin-induced nephrotoxicity, hydration is essential. Short-duration and low-volume hydration in outpatient-administration is safe and effective. Saline loading alone is recommended (125, 126). Cisplatin is not to be given if GFR < 40 ml/min/1,73 m² (normal range 80-125 for ages 18-50). However, if GFR is reduced due to tumour obstruction and improves following relief of renal obstruction (i.e. nephrostomy, stent), cisplatin is to be given in full dose without dose-reduction.

9.1.2 Etoposide

More than 90 % of etoposide is bound to plasma proteins. The risk of myelotoxicity increases with increased unbound etoposide fraction, such as in hypoalbuminemia (127). Patients with albumin levels less than 35 g/L have an increase in unbound etoposide, and more profound toxicity. This should be taken into consideration in patients with hypoalbuminemia. The drug clearance of etoposide seems lower in patients older than 65 years, therefore treatment in elderly patients must be done with regard to their individual tolerance (128).

9.1.3 Bleomycin

The possible risk of bleomycin-induced pneumonitis (BIP) (129) must be taken into account and other regimens considered in patients at risk of BIP.

Bleomycin should not be given to patients with:

- impaired renal function (eGFR<50) since it affects bleomycin elimination
- decreased lung function (lung disease, heavy smoker)
- A cumulative dose > 300 000 units since it is associated with increased toxicity (130)

Another risk factor for BIP is age (> 50 years).

Symptoms can occur weeks to months after start of treatment.

9.1.3.1 Treatment of Bleomycin Induced Pneumonitis

BIP is a severe complication and patients with BIP should preferably be discussed within the SWENOTECA network. The treatment of BIP includes steroids (e.g. 0.5-1 mg prednisolone/kg/day). Pneumocystis prophylaxis with trimetoprim-sulfa is required if high-dose steroids is started.

Imatinib may prevent further pneumonitis and the development of fibrosis and should be considered early in the management of severe BIP. A dose of 300 mg daily is recommended. Once initiated and if the patient is evaluated to respond to the treatment, treatment duration should be 3-6 months

(131). The clinical course of the BIP should be evaluated using lung function tests, such as DLCO/CO-diffusion.

9.1.3.2 Bleomycin and anaesthesia

A negative effect of high inspired-oxygen fractions within days or weeks after bleomycin exposure has been shown in several animal studies. There is however, no unequivocal evidence that the level of oxygenation is of major importance for pulmonary complications during/after surgery in patients having been treated with bleomycin due to metastatic germ cell cancer (132). Another possible mechanism of postoperative BIP is fluid overload. Therefore, perioperative oxygen restriction in patients earlier treated with bleomycin is not necessary. However, oxygen concentration during surgery is to be maintained at the lowest level possible providing adequate oxygenation (average 40% fractional inspired oxygen) and fluid balance has to be monitored closely (133).

9.1.3.3 Bleomycin and scuba diving

Extensive clinical experience in patients resuming diving after bleomycin-containing chemotherapy, combined with the data from surgery in these patients, concludes that resuming scuba diving 6-12 months following uncomplicated therapy with 3-4 courses of bleomycin-containing chemotherapy is acceptable (134).

9.2 High-dose chemotherapy with stem cell support

High-dose chemotherapy (HDCT) has been used in selected patients with germ cell cancer for more than two decades. Still, there is no clear consensus regarding the selection of patients for HDCT and the benefit compared with conventional dose chemotherapy (CDCT) (135). Although several phase I/II and retrospective studies have indicated a possible role for the high dose concept, three randomized trials have not been able to show any significant survival benefit for HDCT vs. CDCT in primary treatment (87, 110, 136).

There are numerous studies supporting the superiority of HDCT over CDCT as salvage treatment, including data from a large international database (137). However, the only prospective phase III trial comparing HDCT with CDCT also failed to show any survival benefit with the HDCT strategy (138), but this study has been criticised for several methodological issues.

9.2.1 The SWENOTECA HDCT experience

During September 1995 to June 2007, 55 patients were treated with HDCT according to SWENOTECA IV (139). SWENOTECA IV used two different high-dose cycles based on carboplatin/cyclophosphamide in combination with either etoposide or thiotepa. Three patient groups were selected for HDCT: A) insufficient response to standard-dose intensified chemotherapy (BEP with addition of ifosfamide, n=36), B) finding of vital cancer at surgery after intensified chemotherapy (n=7), C) relapse after intensified chemotherapy (n=12). In situation A and C two HDCT cycles and in situation B one HDCT cycle was recommended. Overall 27/36 (75%) and 4/12 (33%) patients, respectively, received both of the intended HDCT cycles in situation A and C.

Overall survival after median 7.5 years follow-up was 72%, 100% and 58% in patient groups A, B and C, respectively, while failure-free survival was 64%, 71% and 42%. Three men (5.5%) died during high-dose treatment at three different institutions, all treated before the year 2000. Nephrotoxicity was

the most common non-haematological grade 4 toxicity, affecting five men (9.1%). Haematological toxicity was not more pronounced during the second vs. the first HDCT cycle. The time interval between cycle one and cycle two was median 55 days (range 30-84). The inward time was median 23 days (range 12-54) in both cycles. The recovery time was median 10 days (range 8-17) for the neutrophils in both cycles, and 11 days (range 6-35) for the platelets in both cycles.

In the SWENOTECA VIII care program, the high-dose regimen was changed to two cycles of carboplatin and etoposide. Since 2011 until today, more than 50 patients have been treated with this regimen. Preliminary data shows that 63% of patients received both cycles, suggesting that doublet of the carboplatin-etoposide combination is feasible.

9.2.2 HDCT regimens

Carboplatin and etoposide are the backbone in most high-dose regimens. Some studies have also incorporated cyclophosphamide or ifosfamide. Concern has been raised regarding the increased risk for developing secondary acute leukaemia after high-dose etoposide. Several studies have shown that the risk is acceptably low, with a cumulative incidence in the range 1.4%-2.6%, for cumulative doses of more than 2 g/m² (94, 140, 141).

A single HDCT cycle is probably inadequate to provide optimal cell kill as indicated by the results from a salvage trial (138). Thus, most studies recommend two HDCT cycles. Some studies have included triplet HDCT, but these studies have used intermediate dosage of the active compounds (142, 143). Based on the literature and our own experience, we recommend two cycles of carboplatin and etoposide as described below. The second cycle is scheduled to start as soon as the patient has recovered from the first, usually within 6-8 weeks from start of the first CE.

We recommend a modified Einhorn regimen, which is the regimen with best results and most widely used to date (144).

9.2.3 Treatment recommendations high-dose chemotherapy

Two courses of carboplatin and etoposide, see [addendum XIII](#)

Carboplatin: 8x (absolute GFR+25) mg on days -6, -5, -4 and -3 prior to infusion of stem cells (day 0 = at least 72 hours after the termination of infusion of chemotherapy), to a total dose of 32AUC. MAXIMUM DOSE 1085 mg per day

Absolute GFR is to be used for dosing, based on iohexol clearance or CrEDTA clearance (multiple measure method). The maximum level of absolute GFR to be used is 130 ml/min (concordant with a body surface area of 2.4)

Etoposide: 560 mg/m² on days -6, -5, -4 and -3 prior to infusion of stem cells (day 0 = at least 72 hours after the termination of infusion of chemotherapy), to a total dose of 2240/m². MAXIMUM DOSE 1340 mg per day

See [high-dose chemotherapy regimen \(CE\)](#) for further precautions on dosing and GFR measurement.

9.2.4 Stem cell harvest and practical considerations

The PEI and TIP regimens effectively mobilize stem cells when followed by granulocyte colony stimulating factor (G-CSF), filgrastim, starting 24 hours after the end of chemotherapy and continues until the harvest is completed. The standard dose of G-CSF (filgrastim) is 10 µg/kg for harvesting to enhance the outcome. Pegylated G-CSF is not recommended due to lack of substantial data regarding the mobilizing efficacy.

A practical approach is to start the chemotherapy (PEI or TIP) on a Thursday and the CD34 counting is started on a Monday or Tuesday (day 12 or 13 after start of chemotherapy). The harvesting is generally performed between 8-13 days after the last day of chemotherapy. If the outflow of CD34+ progenitor cells is delayed there will be at least three more working days to harvest before the weekend. However, the chemotherapy scheduling should not be delayed in an urgent clinical situation.

We recommend that at least 7×10^6 CD34+/kg are harvested for two high-dose treatments. The cell dose might have an impact on time to take, and a higher dose may shorten the critical period with difficult complications. However, the lower dose limit for one autologous stem cell support is 2×10^6 CD34+/kg and thus $>4 \times 10^6$ CD34+/kg is the minimum that should be harvested.

In patients with insufficient harvest after chemotherapy, the mobilizing agent plerixafor (Mozobil®) is an alternative (145). This substance is a CXCR4 antagonist which disconnects the progenitor cells from the bone marrow niche and the CD34+ cells surge into the peripheral blood. Filgrastim has to be used concomitantly.

9.3 G-CSF

Both the importance of dose intensity in advanced disease and the well-established risk of hospitalization due to febrile neutropenia after BEP, regardless of treatment indication, have led to an increased use of G-CSF as a primary prophylaxis.

There is concern that the concomitant use of G-CSF increases the risk of BIP in older patients, an observation made in patients treated for Hodgkin's lymphoma (>45 years of age) (146). Data on germ cell cancer patients do not support such an increased risk (147-149). Primary prophylaxis with G-CSF is recommended in patients with disseminated disease since dose intensity is vital. In the adjuvant setting primary prophylaxis with G-CSF is recommended to reduce the risk of febrile neutropenia.

9.4 Thromboembolic events

Approximately 8-20 % of men undergoing treatment for germ cell cancer are diagnosed with thromboembolic events, especially venous, during or shortly after cisplatin-based chemotherapy (150-153). In germ cell cancer, the identified risk factors for thromboembolic events during chemotherapy are abdominal stage C-D, elevated LDH and central venous access.

The literature in this area is sparse (154), but thromboprophylaxis should be considered in the presence of risk factors in the recommendation box below. Thromboprophylaxis should continue until the patient has no signs of remaining germ cell cancer. We recommend low-molecular heparin

(155), alternatively a direct oral anticoagulant in patients with low risk of thrombocytopenia (156, 157).

Due to the risk of thromboembolism with central venous access, peripheral venous access is highly recommended.

Data from the Norwegian “Testicular cancer and Aerobic- and Strength Training trial” (TAST-trial) suggest that patients undergoing chemotherapy for testicular cancer should avoid high-intensity aerobic exercise, to avoid increasing their risk of thromboembolic events (158).

9.4.1 Recommendations thromboprophylaxis

Thromboprophylaxis should be considered for patients with any of the following risk factors

Central venous access (Peripheral venous access is highly recommended)

Abdominal stage C and D

Metastases obstructing vessels

Intermediate or poor prognosis group

Previous thromboembolic event

Age > 60 years

Immobilisation/hospitalisation

Major surgery last 2 weeks

Comorbidity, such as serious infection, cardiovascular disease, renal disease, pulmonary disease, diabetes

10 Surgery other than orchiectomy

10.1 Retroperitoneal Lymph Node Dissection (RPLND)

A multidisciplinary approach is mandatory, and all patients are registered in our prospective population-based study RETROP. The surgical procedures should be carried out at centres with adequate combined competence and experience with germ cell cancer treatment and post chemotherapy surgery.

10.1.1 Indications

A primary RPLND is recommended in patients with persistent marker negative nonseminoma CS IIA, see Flowchart: [Appendix VII](#), in patients with pure teratoma in the testicle and low volume metastatic disease (91, 92), and in patients with CS I with malignant somatic transformations (27).

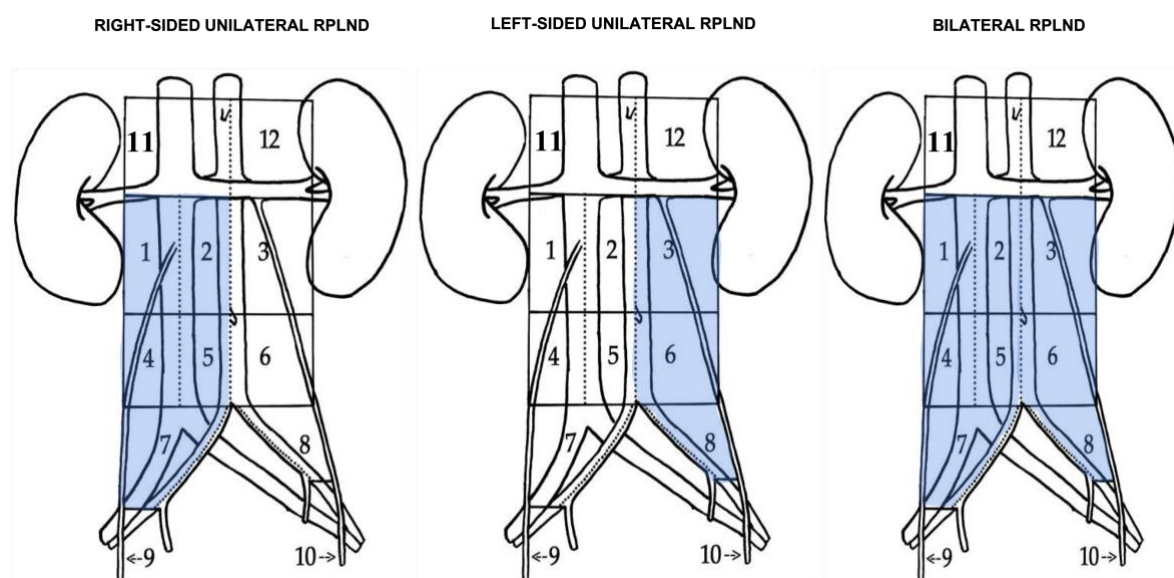
A primary RPLND is a preferred option for seminoma CS IIA-B with 1-2 lymph node 10-30 mm in largest axial diameter, both in primary setting and after relapse in CS1 following surveillance or adjuvant carboplatin (62, 159), Flowchart: [Appendix IV](#).

Since no non-invasive methods, including PET, or prognostic models can predict histology or differentiation in residual masses, RPLND of residual tumour tissue post chemotherapy (largest transverse diameter ≥ 10 mm, marker normalization) is mandatory in nonseminoma (160-164).

In case of residual lesions < 10 mm (largest transverse diameter) after chemotherapy, a PC-RPLND is not mandatory. However, there is a risk of residual cancer or teratoma. A PC-RPLND may be considered if 1) teratoma was present in the primary histology, 2) there is a low degree of shrinking or 3) there is a cystic component in the residual mass in area 1-8.

10.1.2 RPLND Templates

Before deciding on templates, it is important to evaluate both pre- and post-chemotherapy radiology and make sure that all areas with enlarged lymph nodes are excised (165, 166).



10.1.2.1 Right unilateral template

Area 1, 2, 4, 5, 7 and 9

If a radiologically visible mass in area 3 OR 6 was present, both 3 AND 6 should be resected

10.1.2.2 Left unilateral template

Area 3, 6, 8 and 10

If a radiologically visible mass in area 2 OR 5 was present, both 2 AND 5 should be resected

10.1.2.3 Bilateral template

Area 1-8 AND 9 (right-sided primary tumour) OR 10 (left-sided primary tumour)

10.2 Surgical approach

10.2.1 Primary RPLND

For primary RPLND, a unilateral resection is recommended. A nerve-sparing approach is important to reduce the risk of retrograde ejaculation (165, 167).

10.2.1.1 PC-RPLND in nonseminoma

In PC-RPLND for nonseminoma with a residual tumour mass 10-49 mm, a minimum template is a unilateral resection. A lumpectomy is inadequate. PC-RPLND should be carried out within 4–6 weeks after completion of the chemotherapy (168).

A bilateral resection is recommended in patients with residual tumour masses ≥ 50 mm and in retroperitoneal extragonadal germ cell tumours. Suprahilar resections should be performed in selected cases with a suprahilar mass (160, 167).

After completed BEP induction therapy, about 11% of residual tumours are viable cancer, 45% mature teratoma and 44% necrosis or fibrotic tissue (169).

RPLND has traditionally been done as regular “open” surgery. However, minimally invasive RPLND is a feasible option in selected patients (170-172).

10.2.1.2 PC-RPLND (seminoma)

In contrast to nonseminoma, residual postchemotherapy seminoma tumour masses are not generally resected. A cut-off of 30 mm (largest axial diameter) for considering biopsy or resection (if possible) has been used (173). Previous retrospective series have shown viable malignancy rates of 13-42 % in well-defined residual masses >30 mm compared to 0-3 % in masses <30 mm and surgery is technically demanding due to fibrosis and desmoplastic reaction, and it is often incomplete (26-42%)

and associated with increased morbidity. If surgery is needed in this situation it should be in the form of resection (if possible) or biopsy due to a positive PET-CT (77-79, 173-177).

10.3 Pathology results

Pathology results should be reported according to the [pathological examination](#) of the lymph nodes and the [RETROP protocol](#).

In recent reports it has been suggested that the total number of lymph nodes is an independent predictor of disease recurrence after PC-PPLND (178, 179). The pathology report should therefore not only include histology, but also the number of lymph nodes.

10.4 Retrograde ejaculation

With a nerve-sparing approach it is possible to reduce the risk of retrograde ejaculation. It is important in primary RPLND, and a nerve-sparing technique may preserve antegrade ejaculation in most patients (160, 180, 181).

In PC-RPLND it is recommended to attempt to perform a nerve-sparing technique, but it is technically feasible in only 20- 50% of cases due to fibrosis. Importantly, a nerve-sparing technique should not compromise radicality. Ejaculation is preserved in 68-85% and 25-45% of patients undergoing modified unilateral or full bilateral PC- RPLND, respectively (169, 182, 183).

10.5 Extra-retroperitoneal resections

Patients with multiple sites of residual disease postchemotherapy, mostly require resection of masses also outside the retroperitoneum due to discordance rates of histology between retroperitoneal and extra-retroperitoneal residual masses (83, 84). The order of resection should be decided on an individual basis and is mainly dependent on the size of the residual tumours. Large residual masses should be resected first due to the risk of remaining GCC, teratoma, growth and complication (184).

Pulmonary resection is the most frequent surgery after RPLND. If pathological examination after resection of residual masses in one lung show necrosis, resection of contralateral pulmonary lesions is not mandatory (85). However, one should be aware of the possibility of discordant histology, and therefore have a low threshold for surgery in lesion showing signs of growth (86).

Due to a high rate of GCC and teratoma postchemotherapy, surgical resections may be necessary in other metastatic sites as well (e.g. liver, brain, neck).

For teratomas and malign somatic differentiation, surgical resections are the only effective treatment.

10.6 Surgery at relapse and treatment failure

10.6.1 Nonseminoma

10.6.1.1 Marker negative (Mk-) and late relapses

Marker negative relapses are primarily candidates for surgical resections due to a high risk of teratoma. Germ cell cancer other than teratoma will be treated as marker positive relapse, whereas patients with teratomas will be followed without any further treatment.

In late relapses (>2 years after initial treatment followed by complete remission), surgery is considered the most important part of treatment, and increases the rate of cure (185-187).

In patients previously operated with template resections, the focus will be on complete removal of visible tumour changes.

Patients not previously operated, should be operated with a unilateral or bilateral resection depending on tumour location.

10.6.1.2 Surgery after 2nd line or later chemotherapy

All tumour tissue remaining after 2nd or later line chemotherapy should be resected if possible. The completeness of the surgical procedure and the tissue histology are strong predictors for survival (188, 189). The prognosis will be significantly impaired by the finding of undifferentiated tumour tissue.

In case of increasing tumour markers after “salvage” chemotherapy and in lack of chemotherapy alternatives (chemorefractory disease), surgical resection of tumours (“desperation surgery”) may be an option, provided that a complete resection appears feasible (190-193). Such surgery can lead to long-term survival in up to 25% of cases. The prognosis is best in patients with late relapses, moderately elevated AFP, and limited metastases. Surgery is not indicated in patients with aggressively progressing disease and high HCG.

In the case of multiple residual teratomas (e.g., lung) and sudden increase in tumour marker(s) (suspected transformation to germ cell cancer other than teratoma): A PET examination and, if negative, expectancy with new CT/MRI after 4-6 weeks is advised to identify possible site of tumour growth. This will be valuable in order to direct surgical resections.

10.6.2 Seminoma

10.6.3 Patients with residual disease after 2nd line chemotherapy

In patients relapsing after initial chemotherapy for metastatic disease, surgery as part of salvage treatment is of utmost importance, and all remaining lesions should, if possible, be surgically removed. These patients should be discussed within the SWENOTECA network. Therapy should be individualized based on tumour size, location and findings on imaging. Surgery, radiotherapy as well as third line chemotherapy could be considered as part of the treatment strategy.

10.6.4 Surgery at late relapse

Late relapses, defined as disease recurrence more than 2 years after successful initial treatment, are considerably less common in seminomas as compared to nonseminoma (176). The retroperitoneal space is the predominant site of relapse (78, 194, 195). Treatment has to be individualised, based on tumour size, findings on PET imaging and location.

In late relapses with poor response to chemotherapy, surgical resection should be an important part of the treatment strategy (185, 187, 194-197).

10.7 Surgical considerations

Two types of residual masses after chemotherapy have been described and should be identified before surgery (79, 174, 176, 198, 199). One is the resectable well-defined residual mass, which respects the surrounding structures and has been reported to have a higher incidence of germ cell cancer other than teratoma and less complications. The other is the poorly defined “plaque” surrounding the great vessels and resembling retroperitoneal fibrosis. Since these patients have mostly negative pathological findings and a high risk of additional intraoperative procedures (including complex vascular reconstruction), they should not be candidates for surgery. In cases of non-resectable tumours, the options are radiation or chemotherapy, if residual malignant disease is histologically confirmed. Observation is recommended if biopsies are negative.

It is recommended to make a complete resection of well-defined masses (i.e. lumpectomy) when feasible, in combination with random open biopsies to assure a complete evaluation of the retroperitoneum (77, 198, 199). Biopsies alone are not adequate to identify residual disease (200). (201)

11 Extragonadal germ cell tumours (EGCC)

Of all germ cell cancers, 2-5% are EGCC (202-204). The histology is similar to testicular cancers, but the tumour arises outside the testicles, often in midline structures from the brain to the sacrum and is considered a separate entity (205). It is likely that EGCC arises in primordial germ cells that have not completed the migration from the yolk sac via the hindgut to the gonadal fold during foetal organogenesis. This mirrors the typical location in the pineal body, mediastinum, retroperitoneum, bladder, sacrum, and prostate. The most common localization is in the anterior mediastinum followed by the retroperitoneum. EGCC accounts for about 15 % of all tumours in the anterior mediastinum in adults (206).

Extragonadal germ cell cancers of the CNS are not covered by this care program.

In distinction from testicular germ cell cancers, EGCC generally present with a larger tumour burden, more frequent localization in the mediastinum, and a larger proportion of nonseminoma (75-80%). There is no evidence of inheritance, but there is an association with Klinefelter's syndrome. Approximately 1 in 17 patients with mediastinal EGCC is affected by malignant blood diseases, such as acute myelogenous leukaemia and myelodysplastic syndrome (207). These malignant blood diseases are not caused by treatment, and they carry a very poor prognosis. The same chromosomal aberration as seen in testicular germ cell tumours (12p), is often present in the leukemic blasts (206). The median time from diagnosis of EGCC to the diagnosis of these malignant blood diseases are six months.

11.1 Classification and prognosis

The histopathological classification into seminoma and nonseminoma is similar to testicular cancers and mirrors the different levels of maturation in the normal embryogenesis (208, 209). In a meta-analysis of 635 patients with EGCC, 83 % had nonseminoma (197).

The prognosis of EGCC follows the [IGCCCG criteria](#), with mediastinal nonseminoma EGCC always classified as poor prognosis. Fifty-four percent were localized in the mediastinum and 45 % in the retroperitoneum (210). Median age at diagnosis was 28 and 30 years for mediastinal and retroperitoneal nonseminoma, respectively. Metastatic disease was present at diagnosis in 50% of the patients with primary mediastinal EGCC and in 76% of the patients presenting with retroperitoneal tumour, respectively.

11.2 Diagnostics

See [Appendix X](#).

As there is no primary testicular tumour, most patients are diagnosed due to symptoms from growing tumour masses in the mediastinum or retroperitoneum. The distinction between a primary testicular tumour and EGCC has implications both for the treatment and prognosis, and the diagnostic staging should be thorough to reveal possible pathology in the testis.

Both testicles should be assessed with ultrasound scanning to reveal possible pathology. In addition to an evident primary tumour in the testicles, a pathological ultrasound result may include signs of a burned-out tumour. Bilateral biopsy is recommended in all patients. This should, however, not delay the start of therapy and may be performed two years after the end of chemotherapy. Biopsies are performed both due to the possibility of an undetected primary tumour, and the presence of GCNIS which may result in the later risk of metachronous testicular cancer, which has been reported to be about 10% (211, 212). Previously, many EGCC tumours, in particular retroperitoneal EGCC, may in fact have originated from a primary testicular cancer, in part explaining the better prognosis of retroperitoneal EGCC compared to EGCC in other sites (213, 214). If there is clinical suspicion of Klinefelter's syndrome in patients with mediastinal tumours, a chromosomal analysis should be considered.

A tumour biopsy is required before start of treatment unless tumour markers are elevated, or the patient is in a life-threatening condition.

11.3 Treatment

11.3.1 Chemotherapy

For all EGCC, the treatment Flowchart for the respective prognostic group should be used. Primary nonseminoma mediastinal EGCC tumours are classified and treated as poor-prognosis testicular cancer with non-pulmonary visceral metastasis. Patients with EGCC should only be treated by a centre with experience in advanced germ-cell tumours. Teratomas are treated by surgical resection only and chemotherapy has no role unless tumour markers are elevated.

Most studies on poor-prognosis metastatic nonseminoma germ cell tumours have included mediastinal EGCC. The standard treatment of all poor prognosis patients has been BEP x 4. However, in nonseminoma mediastinal EGCC, PEI or VIP chemotherapy has been advocated to avoid Bleomycin, as these patients will require extensive thoracic surgery for residual masses after chemotherapy (215, 216). The combination of Bleomycin and thoracic surgery increases the risk for developing bleomycin-induced pneumonitis (217), see [9.1.3](#). As with testicular GCC, data show that a favourable decline of serum tumour markers strongly predicts improved treatment outcomes in EGCC. There are data indicating a benefit of treatment-intensification in the case of delayed tumour marker decline in poor-prognosis patients, including EGCC (87).

For seminoma EGCC in the good prognosis group, the treatment recommendation is BEP x 3 or EP x 4. In seminoma EGCC in the intermediate prognosis group, the treatment recommendation is BEP x 4 or PEI x 4.

As the SWENOTECA protocols up to recently have not included EGCC, we lack our own data to support the treatment of this group based on tumour marker kinetics. The SWENOTECA VIII guideline for patients in the poor prognosis group with non-pulmonary visceral metastasis recommends treatment intensification, compared to the former SWENOTECA IV protocol. We therefore choose to treat poor-prognosis EGCC as poor-prognosis testicular cancer with non-pulmonary visceral metastasis.

11.3.2 Surgery

In patients with nonseminoma EGCC arising from the mediastinum, surgical resection of all post-chemotherapy residual masses is mandatory and should be performed without delay after chemotherapy

The residual mediastinal tumour is often large, and there are often other residual masses. Histological analyses of surgically removed residual masses in these patients have revealed germ cell cancer other than teratoma in 66% of patients and teratoma in 22% (218). More often than in other germ cell tumours, there is teratoma with malignant transformation in residual masses. This is an entity with particularly poor prognosis, and where surgery is the only chance of cure. If complete resection is technically feasible, surgery seems to be beneficial even in patients with elevated tumour markers.

In patients with nonseminoma EGCC arising from the retroperitoneum, resection of residual masses has shown germ cell cancer other than teratoma in 25% of patients and teratoma in 16% of patients. This is a higher proportion than in patients with residual masses following treatment of gonadal metastatic disease. A full bilateral RPLND is therefore warranted in these patients.

Seminoma EGCC may not require post-chemotherapy surgery (215, 219, 220).

The indications for adjuvant chemotherapy in the case of germ cell cancer other than teratoma in residual lesions in patients within the intermediate and poor prognosis are uncertain, as there are no strong evidence-based data. Both immediate post-surgery adjuvant chemotherapy and close surveillance may be options. The most important focus should, however, be to obtain radical surgery of all residual lesions.

11.3.3 Salvage treatment

Salvage therapy in retroperitoneal EGCC follows the recommendations for gonadal germ cell cancer. For mediastinal nonseminoma tumours, salvage chemotherapy leads to long-term remissions in less than 10 % of the patients and therefore one should consider surgical resection even if tumour markers are elevated (210, 215, 219).

11.3.4 Registration and follow-up

There is a separate registration form for the patients with extragonadal germ cell cancer, but the other forms are the same for primary testicular and primary extragonadal location of the tumour. The follow-up schedule is the same as for metastatic germ cells cancer. In mediastinal EGCC imaging with MRI or CT of the mediastinum should be scheduled at the same time as imaging of the retroperitoneum.

12 Follow-up

Clinical examination is individually designed.

The primary aim of the follow-up is the diagnosis of recurrence at the earliest possible time, to be able to cure the patient using as little therapy as possible. Another important aim is to diagnose complications and trying to relieve symptoms from the disease and treatment. An adequate follow-up is dependent on profound knowledge of the disease with regard to histology, treatment and expected mode of recurrence as well as possible side effects. The intervals and mode of controls are typically adapted to stage, histology, treatment, timely risk of recurrence, and expected risks of side effects. All follow-up is estimated from end of last treatment given. This can be initial treatment, or treatment of possible relapse.

From the SWENOTECA experience, the risk of relapse is very low after 5 years after the end of therapy, with some exceptions stated below. Therefore, this protocol advocates shorter follow-up than previous SWENOTECA protocols. Adjuvant Carboplatin in seminoma clinical stage I may delay metastatic disease, thus these patients should have additional 7-year and 10-year follow-up visits. The following patients treated for metastatic nonseminoma should have additional 7-year and 10-year follow-up visits: intermediate and poor prognosis, persistent residual tumour at 5-year follow-up, teratoma in residual tumour resection, or teratoma in the testicle and no RPLND. For some patients with multiple recurrences with teratoma, and for those with residual tumours not available for resection (nonseminoma) lifelong follow-up may be indicated.

In the addendum, the schedules for minimum follow-up according to a number of standard scenarios are presented, but one must keep in mind that a number of patients need to have their schedules individualised because of situations not taken into account for in the standard schedule.

[Follow-up schedule for seminoma patients](#)

[Follow-up schedule for nonseminoma stage I surveillance](#)

[Follow-up schedule for nonseminoma stage I, adjuvant BEP](#)

[Follow-up schedule for nonseminoma patients after treatment for metastatic or recurrent disease](#)

13 Treatment of Relapse or Progression after Standard Combination Chemotherapy

If feasible, histological verification should be performed, most importantly in the tumour marker negative setting.

Treatment depends on the site of relapse and previous treatment.

The SWENOTECA X [follow-up form](#) must be filled in and sent to the regional testicular cancer registry immediately if a relapse is detected.

It is very important to detect any deviation from the postulated relapse rates and patterns as early as possible, in order to adjust the treatment and/or follow-up program, if indicated.

13.1 Relapse after Surveillance or Adjuvant chemotherapy

Relapse after initial clinical stage I, should be treated as initial metastatic disease, according to stage and prognostic group. See [Chapter 8](#). A suspected tumour marker negative recurrence should be histologically confirmed prior to starting systemic treatment.

13.2 Relapse after initial Radiotherapy

Relapse after initial clinical stage I or stage II treated with radiotherapy, should be treated as initial metastatic disease with chemotherapy or surgery, according to clinical stage and prognostic group. See [Chapter 8](#).

13.3 Prognosis of Relapse or Progression

A publication from the International Prognostic Factors Study Group, using data from 1984 relapsing patients, identified prognostic variables in patients relapsing after conventional dose chemotherapy (221). Patients from the SWENOTECA group were included in the analysis. These variables form the [IPFSC-score](#) which can help classify patients into prognostic categories with regard to PFS and OS. Patients in the very low risk (only seminoma) or low risk prognostic groups category have a 2-year PFS > 50 %, and 3-year OS of >65 %. The intermediate-, high- and very high-risk prognostic groups have 2-year PFS of 40 %, 26 % and 6 %, respectively, and 3-year OS of 58 %, 27 % and 6 %, respectively. A retrospective study, from the same group, looking at the outcome of salvage treatment in 1594 patients has been published (135). The analysis indicated that high dose carboplatin-based salvage treatment might benefit patients with regard to both PFS and OS. The benefit in OS was seen in the intermediate-, high- and very high-risk prognostic groups.

Prognostic score for patients with relapsing vital germ-cell tumours. IPFSC-score.

Parameter	Score Points				
	-1	0	1	2	3
Primary site		Gonadal	Extragenital		Mediastinal NSGCT
Prior response		CR/PRm-	PRm+/SD	PD	
PFI, months		> 3	≤ 3		
AFP salvage		Normal	≤ 1000	> 1000	
hCG salvage (at relapse)		≤ 1000	> 1000		
LBB*		No	Yes		
Primary histology	Pure SGCT	Non SGCT			
Regroup score sum into categories: -1 = very low-risk; 0 = low-risk; (1-2) = intermediate-risk; (3-4) = high-risk; (5-) = very high-risk *LBB=Liver, bone or brain metastases					

13.4 Conventional Dose Salvage Chemotherapy

The currently favoured salvage regimen is paclitaxel-based standard-dose chemotherapy (TIP). In patients with favourable prognostic features, about 70% of patients can be cured by this regimen (222).

Several other regimens have curable potential in relapsing germ cell cancer. These include regimens contain platinum/etoposide/ifosfamide (223), gemcitabine/oxaliplatin (224-226), gemcitabine/paclitaxel (227), gemcitabine/oxaliplatin/paclitaxel (228, 229), oxaliplatin/irinotecan (230) and gemcitabine/cisplatin/paclitaxel (231).

EMA-CO may be an option in patients with relapsing disease expressing β -hCG, with some patients achieving CR after relapse following HDCT (232).

13.5 HDCT Salvage Treatment

High-dose chemotherapy (HDCT) has been increasingly used as salvage treatment for patients with relapse after primary cisplatin-based chemotherapy. Several phase I/II studies and retrospective studies have evaluated the effect of HDCT in patients with relapse and/or cisplatin-refractory disease. There is considerable variation in study design, dose intensity and patient selection, and thus

outcome; the reported failure-free survival range from 12% to 63%. Einhorn et al. have published the largest retrospective series, including 184 patients treated with salvage tandem HDCT (carboplatin and etoposide) from 1996 to 2004 (233). Resection of residual masses was performed whenever technically feasible. After a median follow-up of 48 months, 63% were continuously disease-free. This is a higher proportion than previously reported in phase II studies and may in part be explained by the exclusion of patients with primary mediastinal tumours or those with late relapse. In addition, 45% of patients who were refractory to cisplatin remained disease-free, confirming that HDCT can overcome cisplatin resistance in a considerable number of patients.

13.6 Treatment of Relapse

See flowchart, [Appendix XIII](#).

All patients relapsing after initial chemotherapy for metastatic disease should immediately be referred to a centre experienced in treating metastatic germ cell tumours.

If a pathological level of AFP, β -hCG or PLAP is detected without evident metastasis on CT thorax/abdomen/pelvis, additional MRI imaging of the brain and spine should be performed. Ultrasound of the contralateral testicle should also be performed.

Repeated tumour markers should be performed to exclude false positives.

If unequivocal pathological levels of the specific tumour markers AFP, β -hCG (but not LDH) or PLAP are confirmed, with or without clinical or radiological evidence of metastases, salvage chemotherapy should be instituted as soon as possible.

Biopsy of any evident metastatic/tumour lesions is advisable, but not mandatory if there is clear and persistent serum tumour marker elevation.

13.7 Salvage Treatment Metastatic Disease

SWENOTECA uses the [IPFSC](#) score, treatment with salvage chemotherapy is determined by prognostic group and earlier treatment. Patients with a favourable prognostic score will most likely be cured by conventional dose taxane-based regimen (TIP). However, in selected cases with small volume nodal seminomatous relapse, radiotherapy might be an option.

Patients with intermediate prognostic score or worse have a 2-year PFS of 40 % and hence, high-dose chemotherapy is recommended as primary salvage chemotherapy.

If there are indications of metastatic disease on imaging without elevation of serum AFP, β -hCG or PLAP, a biopsy/surgery should be performed to obtain histological verification. If a suspected lesion is relatively stable and is PET-negative the lesion may be closely observed.

Further information can be found in the following sub-chapters, on [High-dose treatment](#) and [Brain metastasis](#).

13.8 Post-Chemotherapy Surgery or Radiotherapy

13.8.1 Nonseminoma

In the relapse situation, surgical removal of post salvage chemotherapy lesions is mandatory. Patients with relapse following initial metastatic disease, surgical removal of remaining lesions is mandatory in patients with nonseminoma.

13.8.2 Seminoma

Consolidating treatment after chemotherapy in the form of surgery or radiotherapy should not be used unless remaining lesions are biopsy-verified to contain germ-cell cancer other than teratoma. Even PET positive lesions should be biopsied as PET can be false positive. In patients with advanced seminoma, surgery after chemotherapy may be technically challenging, but if feasible surgery should be chosen over consolidating radiotherapy.

13.9 Palliative treatment

About ten patients annually die of testicular cancer in Norway and Sweden. Before a patient is classified as palliative the patient should be discussed within the SWENOTECA-network. Response to palliative treatment is often short, thus alleviation of symptoms is desired (234). Radiotherapy will almost always give good palliation of local symptoms.

Another option is oral etoposide 50 mg/m² daily, until progression or unacceptable toxicity (235).

Palbociclib (or other CK4/6 inhibitors) is probably efficient in unresectable, growing teratoma or teratoma with somatic differentiation, with median PFS at 23 weeks for patients with unresectable teratoma in a small phase II trial (236). So far, the experience within SWENOTECA with palbociclib in this situation is very limited, and candidates should be discussed within the SWENOTECA network.

Currently immunotherapy do not have any place in the treatment of refractory disease (237).

Tyrosine kinase inhibitors may also be an option, with some patients experiencing good responses (238).

14 Long-term complications and follow-up after treatment for testicular cancer

Patients should be reassured that in most cases, long-term overall health-related quality of life is similar to that in men who have not undergone treatment of testicular cancer ([ESMO](#)). Some side effects from testicular cancer treatment may, however, emerge several years after treatment.

When follow-up for relapse is ongoing:

- Testosterone, SHBG, LH and FSH controls year 1, 3, 5 and up to 10 years according to follow-up schedules, regularly for patients on testosterone replacement therapy and at occurrence of symptoms of hypogonadism for others
- Metabolic screening (lipids, fasting glucose, HbA1c and blood pressure) at 1 year and last follow-up
- At the last oncological follow-up, all patients should receive a patient care plan that summarizes the previous treatment, the most important long-term complications and recommendations for further follow-up, [Appendix XVII](#)

14.1 Controls at the general practitioner

In patients treated with chemotherapy for metastatic disease or radiotherapy we advise the patient to undergo regular examinations at the general practitioner minimum every 5 years after completion of oncological follow-up, and more frequently in the case of pathological findings. The purpose of these controls is to prevent, identify and possibly treat complications of the previous cancer treatment. These controls may include:

- Anamnesis and initiation of primary or secondary prophylaxis regarding cardiovascular risk profile as for the general population recommendations, and symptoms of hypogonadism, cardiovascular disease and fatigue
- Advice about lifestyle factors such as smoking cessation, healthy diet and physical activity.
- Measurement of blood pressure, height/weight (BMI)
- Blood samples: Fasting lipid profile (total cholesterol, HDL and LDL cholesterol, triglycerides), glucose, HbA1c, and sex hormones if hypogonadal symptoms (testosterone, SHBG, LH and FSH)

14.2 Cardiovascular disease (CVD)

Mortality from CVD is higher in testicular cancer survivors (TCS) than in the general population (239-241). Cardiovascular side-effects can both be related to treatment toxicity, and low testosterone levels with increased risk for the metabolic syndrome (242, 243). Men previously treated with cisplatin-based chemotherapy have a 2-3-fold increased risk for CVD in comparison to men treated with surgery only or the general population in several studies. The risk for CVD is increased also after infradiaphragmatic irradiation, but results are conflicting (242-244). The absolute risk for CVD several years after cytotoxic treatment is 6-10% (243, 244). Combination of both chemotherapy and radiotherapy is particularly harmful, with an absolute risk for CVD at 20% several years after treatment (243). Cisplatin-based chemotherapy is also associated with an increased prevalence of

hypertension and the metabolic syndrome, while radiotherapy is associated with an increased prevalence of diabetes (243, 245, 246).

Endothelial and inflammatory markers, e.g. fibrinogen and von Willebrand factor, are increased in men treated with cisplatin-based chemotherapy, while high-sensitivity C-reactive protein (hs-CRP) is increased several years after treatment with radiotherapy (243, 247, 248). These findings indicate that endothelial dysfunction might be a possible link between cytotoxic treatment and atherosclerosis.

14.3 Second cancer

There is a risk of a new germ-cell cancer in the contralateral testicle, and 2-5% of testicular cancer patients develop a second germ cell cancer in the remaining testicle (249).

There is an increased risk for second non-germ cell malignant neoplasms after cytotoxic treatment for testicular cancer (250), with a considerable latency from cancer treatment to second cancer occurrence (58, 241). The excess risk of second cancers after cisplatin-based chemotherapy or radiotherapy has been reported to be 40-80 % (58, 251-253), with even higher excess risks in patients who have received combined chemotherapy and radiotherapy (standardized incidence ratio > 2). An increased risk for cancers in the bladder, kidney, lung and soft tissue has been reported after 2 cycles or more with cisplatin-based chemotherapy. Adjuvant chemotherapy with BEP x 1 and carboplatin x 1 has not been shown to increase the risk of second cancers, but the observation time is limited with a median follow-up of 9.5 years (58).

Radiotherapy has led to an increased risk of cancer in organs localized in relation to previous radiotherapy fields, including gastrointestinal tract, pancreas, liver, lung, kidney and bladder.

In a recent large Norwegian study among 5600 testicular cancer survivors, a 28% excess risk of second cancer after surgery alone compared with the general population was reported, with significantly increased risks of thyroid cancer and melanoma. The excess risk for second cancer after surgery alone could in part be explained by surveillance bias. However, a genetic susceptibility and/or environmental factors predisposing for testicular cancer as well as other malignancies are likely to be contributing factors (254).

14.4 Fertility and hypogonadism

14.4.1 Fertility

- All men aged < 56 years who are interested in future parenthood should be offered cryopreservation of sperm since subfertility is common among men diagnosed with testicular cancer (255).

Cytotoxic treatment may negatively affect both the fertility and the levels of sex hormones (256). Results from a large Norwegian follow-up study among TCS have shown that fertility decreases with increasing treatment intensity (257). Still, nearly half of the males treated with large cumulative cisplatin doses had become fathers after testicular cancer treatment without using cryopreserved sperm. Carboplatin treatment did not negatively affect sex hormones or spermatogenesis in a study

of 54 treated males (258). In addition, a recent Swedish study did not find any long-term effects on sperm quality after adjuvant chemotherapy with BEP x 1 or carboplatin x 1 (9).

It is considered safe to conceive six months after finished chemotherapy. Chemo- and/or radiotherapy treatment did not increase the risk of malformations in children fathered by men treated for testicular cancer, when compared to males in surveillance only (259).

If a patient conceives during or shortly (< 6 months) after receiving chemotherapy the potential risks for the foetus should be thoroughly discussed with experts within the field. The clinical data are sparse and insufficient to provide a standard recommendation on how to manage such a pregnancy.

14.4.2 Retrograde ejaculation

Retrograde ejaculation occurs in 59% of patients after bilateral RPLND and 32% after unilateral RPLND (169). Patients should be informed prior to surgery. The incidence has been reduced after the introduction of nerve-sparing surgery techniques (260).

For men who desire to achieve fatherhood, treatment with α -sympathomimetics such as phenylpropanolamin or imipramin should be considered as these substances may reverse the retrograde ejaculation (261).

14.4.3 Hypogonadism

It is important to identify symptoms related to hypogonadism and offer treatment to relieve symptoms. Primary endocrine hypogonadism is prevalent in 5-13% of patients after orchiectomy, increasing to 11-27% after chemotherapy (262) ([ESMO](#)).

Typical symptoms are:

- decreased libido
- erectile dysfunction
- gynecomastia
- reduced need of shaving
- loss of energy
- dysthymia
- reduced muscle strength
- increased body mass index

Endocrine hypogonadism is associated with hypertension, obesity, the metabolic syndrome and diabetes (263, 264) and probably also with increased mortality rates (265, 266).

14.4.3.1 Examinations

Two morning sex hormone measurements should be performed to confirm hypogonadism (267). SHBG, LH and FSH should be evaluated in addition to testosterone. Free testosterone index may be calculated, (testosterone (nmol/l) x 100)/SHBG (nmol/l) since this can reflect the biologically active testosterone level better.

14.4.3.2 Treatment

- The current recommendation is that testicular cancer survivors with repeatedly low testosterone levels (according to local laboratory guidelines and age) (268) AND clinical symptoms should be offered testosterone replacement therapy for a trial period of three to six months ([ESMO](#)) and then be evaluated for its effects. Testosterone substitution is administered to relieve hypogonadal symptoms, and there are no data indicating a decreased cardiovascular risk with substitution.
- After bilateral orchiectomy and with established testosterone deficiency after treatment for GCNIS, lifelong testosterone substitution is warranted.
- Men with considerable clinical symptoms (decreased libido, erectile dysfunction, loss of energy) but with testosterone levels within the normal range, may benefit from testosterone substitution. In case of hypogonadal symptoms and significantly elevated LH but normal testosterone levels, consider compensated hypogonadism and potential treatment. Testosterone substitution in these two situations should be discussed with an endocrinologist.

Treatment with injections every 10-12th week or daily transdermal gel is available and individual judgements should govern decisions, dose and treatment interval. Prostate cancer should be ruled out prior to treatment (PSA) and a haematocrit above 53% should not be present. Congestive heart failure should be well medicated. In case of wish for future fatherhood, substitution with testosterone decreases sperm viability and delayed treatment start should be considered. An endocrinologist or andrologist can be consulted. Haematocrit and blood pressure should be assessed during follow-up.

14.5 Fatigue

Fatigue-related symptoms are the most distressing symptoms among long-term testicular cancer survivors, with 49% of survivors reporting lack of energy (269). Chronic fatigue is defined as a distressing, persistent subjective sense of physical, emotional and/or mental tiredness related to cancer and/or cancer treatment (270). Of note, chronic fatigue is not possible to measure objectively, its diagnosis relies on self-report, and several instruments are available, e.g. the Fatigue Questionnaire.

The prevalence of chronic fatigue has been evaluated longitudinally in 812 Norwegian TCS (271). The prevalence of chronic fatigue increased from 15% median 11 years after treatment, to 27% median 19 years after treatment. Prevalent neuropathy, Raynaud-like phenomena, low testosterone and higher levels of anxiety and depression increased the risk of chronic fatigue, while physical activity had a protective effect on chronic fatigue. Of note, treatment modality was not associated with chronic fatigue in multivariate analyses.

It is recommended that all testicular cancer survivors are evaluated for the presence of fatigue. For those who present with moderate to severe fatigue, a more comprehensive assessment including evaluation of, and possibly, treatment of contributing factors (e.g. pain, anaemia, hypogonadism) should be performed (270). As for treatment strategies, physical activity has been proved to reduce the prevalence of chronic fatigue in long-term TCS, and is strongly recommended (272). There are evidence supporting the use of psychosocial interventions. There are no data supporting the use of

pharmacologic interventions in the treatment of chronic fatigue, although randomized studies have shown effect of open-label placebo to improve cancer-related fatigue (273, 274).

14.6 Other long-term complications

Ototoxicity and neurotoxicity may occur after cisplatin treatment, these side-effects should however not contraindicate curative treatment.

A considerable number of TCS suffer from other long-term complications (nephrotoxicity, neurotoxicity, ototoxicity, pulmonary toxicity and psychosocial problems) (217, 275, 276). Both treatment with large cisplatin doses (>850 mg) and smoking increase the risk for long-term ototoxicity, neurotoxicity and pulmonary toxicity (277).

14.6.1 Ototoxicity

After treatment of metastatic disease with BEP, 20-25% of patients report long-term hearing impairment and tinnitus (278), in particular at higher frequencies. Increasing age is an important factor for hearing loss regardless of treatment (279). Factors that can increase this risk includes severe noise exposure prior to treatment, co-treatment with other ototoxic agents (such as aminoglycosides) and abnormal renal function. Unfortunately, no drugs have yet been identified that relieves symptoms ([ESMO](#)). Men with treatment-induced ototoxicity (tinnitus, hearing impairment) should avoid noisy environments

Consultant with ear-specialist for tinnitus treatment or hearing-aid should be considered

14.6.2 Neurotoxicity

Peripheral sensory neuropathy is seen in 5% of patients after once cycle of BEP (280) and 25-35% after three to four cycles of BEP (73). Neuroprotective therapies have been and are currently tested, but none are included in routine clinical care ([ESMO](#)). Potential therapeutic agents are duloxetine (281), tricyclic antidepressants and anticonvulsants (282).

14.6.3 Raynaud's phenomenon

Raynaud's phenomenon can be detected in patients receiving bleomycin and/or cisplatin and should be handled preferably conservative and by informing patients of this. In case of severe problems low dose calcium blockers can be used. Several other option, such as topical nitroglycerine, could also be considered (283).

15 Stromal Testicular Tumours

Stromal tumours are not included in the SWENOTECA registry.

Stromal testicular tumours are rare and compromise only 2-4% of all testicular tumours in adults. These are mainly tumours classified as Leydig cell tumours and Sertoli cell tumours. However, a number of different tumours have been classified (284).

- Leydig cell tumour
- Malignant Leydig cell tumour
- Sertoli cell tumour
- Malignant Sertoli cell tumour
- Granulosa cell tumour
- Thecoma/fibroma group of tumours
- Gonadoblastoma (tumours containing germ cell and sex cord/gonadal stromal tissue)
- Mixed and unclassified sex cord stromal tumours

As these are rare tumours, limited data exists and the following recommendations are mainly based on [EAU guidelines](#).

15.1 Leydig cell tumour

Leydig cells produce testosterone regulated by LH (luteinizing hormone). Leydig cell tumours compromise only about 1-3 % of all testicular tumours (285). This tumour is predominantly seen in men between the age 30 and 60 years. In children they are associated with Klinefelter's syndrome and may be bilateral. Leydig cell tumours are the most predominant of the gonadal stromal tumours. They are usually benign but may have a malignant potential. The malignant Leydig cell tumours can be characterized by the following histopathologic features which are regarded as risk factors(286)

- Diameter > 5 cm
- Cellular atypia
- Increased mitotic rate
- Increased MIB-1 expression
- Necrosis
- Vascular invasion
- Infiltrative margins
- DNA aneuploidy

Metastatic disease will always imply malignant disease and about 10% of Leydig cell tumour patients have metastatic disease. Patients with Leydig cell tumours without malignant features have a very low risk of metastases.

15.1.1 Diagnosis

Leydig cell tumours often presents as an enlarged testicle. 80% of the patients have hormonal disturbances with low testosterone, increased oestradiol and increased levels of LH and FSH (287). This may explain why about 30% of the patients also have symptomatic gynecomastia. Leydig cell tumours must be separated from multinodular and often bilateral lesions seen with the androgenital syndrome (288).

Diagnostic work up consists of blood samples for testicular tumour markers (AFP, β -hCG, LDH) and hormones (testosterone, LH, FSH, oestrogen and progesterone), ultrasound of the testicles as well as CT scan of thorax, abdomen and pelvis.

15.1.2 Treatment

Standard orchiectomy is usually performed. Organ-sparing surgery can be considered especially with bilateral tumours (289). In the presence of malign histopathologic characteristics, adjuvant RPLND should be considered to prevent development of metastatic disease (290). In clinical stage 2, RPLND is recommended although long term prognosis may be poor (291). Patients with metastatic disease respond poorly to both chemotherapy and radiotherapy. Hence, surgery must be considered.

15.2 Sertoli cell tumours

Sertoli cell tumours compromise less than 1% of testicular tumours. They present at an average patient age of 45 years and is only rarely seen under the age of 20 years. The latter are associated with androgen resistance syndrome and Peutz-Jeghers syndrome (292). Sertoli cells are supportive cells in the seminal canals in the testicle and nourishes mature semen. About 10- 20% of Sertoli cell tumours are malignant, and 10-12% present with metastatic disease (293).

Malignant characteristics are as follows:

- Diameter > 5 cm
- Nuclear atypia
- Increased mitotic activity
- Necrosis
- Vascular invasion

Metastatic disease is rare even with the above-mentioned malignant characteristics. Three subgroups have been identified: Large cell calcifying Sertoli cell tumours, Intratubular large cell hyalinizing Sertoli cell tumours and malignant Sertoli cell tumours (284, 292).

15.2.1 Diagnosis

Sertoli cell tumours are usually unifocal. Hormonal changes are rare and tumour markers AFP and β -hCG are always within normal range. The diagnostic work-up is as described above for Leydig cell tumours.

15.2.2 Treatment

Orchiectomy or organ-sparing surgery is advised, the latter especially with small bilateral tumours. Organ-sparing surgery is only an option if remaining testicular tissue has sufficient endocrine and exocrine function. If the tumour has malignant characteristics, adjuvant RPLND may be considered. Patients with metastatic disease respond poorly to both chemotherapy and radiotherapy.

15.3 Granulose cell tumours

Adult granulose cell tumours of the testis are rare and present with isolated unilateral testicular mass and occasionally with gynecomastia(294).

About 10% of adult granulose cell tumours are malignant and RPLND is recommended if metastases to retroperitoneal lymph nodes are detected. A risk factor for malignant disease is size (> 46 mm), and lymphovascular invasion. They also usually have a higher mitotic index, necroses in the tumour and more frequently present with gynecomastia.

15.4 Fibrothecoma

Fibrothecoma are considered benign and are cured with excision (295).

15.5 Gonadoblastoma

Classical gonadoblastoma occurs almost entirely in dysgenetic gonads of individuals who have a disorder of sex development. Forty percent of these tumours are bilateral. A variant contains both sex cord and germ cell elements, and the prognosis is determined by the germ cell component (296). In these cases, treatment and follow-up is recommended as for germ cell cancers.

15.6 Other testicular tumours

Prepubertal teratoma has a benign behaviour and is considered to be non-GCNIS-related(292). It occurs mainly in children and is thus not covered by this program. Prepubertal teratoma may however also occur in adults and should be classified as a benign tumour.

15.7 Spermatocytic tumours

Spermatocytic tumours are rare and the average age is 55 years. Gain of chromosome 9 is the only consistent chromosomal anomaly of spermatocytic tumours. As these tumours never metastasize, treatment is by orchiectomy alone and no follow up is needed (297, 298). An exception is tumours that have undergone sarcomatous transformation which may metastasize and may require aggressive multimodal treatment.

15.8 Follow up

Patients with tumours classified as benign, need not be followed for the risk of metastatic disease. However, patients should be informed that future hypogonadism might occur.

Patients with tumours with malignant histological features should be monitored with abdominal imaging every six months for three years.

16 Radiotherapy

The dose prescription, recording and reporting should be done according to ICRU report 50 and the supplementary ICRU reports 62 and 83 (299-301).

16.1 Fields and Doses

16.1.1 Seminoma CS I

1.8 Gy x 14, to a total dose of 25.2 Gy, 5 days weekly, to the para-aortic lymph nodes and the ipsilateral common iliac- and the external iliac lymph nodes.

Note: If T4 tumour or previous inguinal or scrotal surgery, also the ipsilateral inguinal lymph nodes should be treated.

16.2 Seminoma CS II

CS II A: 2 Gy x 15, to a total dose of 30 Gy, 5 days weekly, to the para-aortic lymph nodes and the ipsilateral common iliac- and the external iliac lymph nodes.

CS II B: 2 Gy x 15 according to CS IIA with an additional boost to enlarged lymph nodes of 2 Gy x 3 to 6 Gy. SIB preferably to be used, 2,4 Gy x 15.

Note: If T4 tumour or previous inguinal or scrotal surgery, also the ipsilateral inguinal lymph nodes should be treated.

16.3 Patient position and fixation

The patient is placed in the supine position, fixated according to local practice for reproducible positioning of the patient during the whole treatment process. Mark the orchiectomy scar with a pewter thread. For patients in reproductive age, a lead shield should be used to protect the contralateral testis from external scattered radiation. The penis should be moved out of the treatment fields.

16.4 Radiotherapy treatment technique

A CT-based 3-dimensional (3D) planned radiotherapy is mandatory. The standard treatment has been two opposed anteroposterior-posteroanterior, AP-PA, fields. The use of volumetric arc therapy (VMAT) reduces the delivered dose to active bone marrow but may increase the mean dose and the dose delivered to 50% of the volume for the kidneys, liver and bowel compared to two AP-PA fields (302) which may increase the risk of secondary malignancy (303, 304). Due to the long-term survival of patients with germ cell tumours close vigilance in regard to doses to organs at risk must be observed.

The CT-based plan of the fields is generated based on vascular anatomy as the lymph nodes follow the vessels (aorta, vena cava inferior, ipsilateral renal vein, the common iliac and external iliac vessels). A prospective cohort study performed by the German Testicular Cancer Study Group showed no pelvic relapses with a modified inferior border of the iliac fields to the top of the acetabulum, which is also recommended by the EGCCCG (57, 305). The upper border of the treatment volume is the top of the 12th thoracic vertebra (306).

16.4.1 Beam quality

The 3D conformal RT should be delivered with a minimum of 10 MV photon quality.

16.4.2 Target volumes and organs-at-risk (OAR) volumes

GTV (Gross tumour volume) should be defined as the volume of any lymph node enlarged due to metastasis (i.e., CS IIA).

16.4.3 Target volumes

The CTV in the para-aortic region should include the para-aortic lymph nodes from the upper border of the 12th thoracic vertebra to the aortic division and is defined as the combined inferior vena cava and aorta volume including visible lymph nodes and any GTV with an additional symmetrical margin of 1.4 cm. Similarly, for the renal vein volume except for no expansion laterally.

If the ipsilateral common iliac- and the external iliac lymph nodes are to be treated, the CTV should be extended to include the combined volume of the common iliac and external iliac vessels to the level of the top of the acetabulum, including visible lymph nodes and any GTV, with an additional margin of 1.4 cm in all directions.

In case of previous inguinal or scrotal surgery or in the rare event of a T4 tumour, the CTV should include both the ipsilateral common iliac- and the external iliac lymph nodes and the ipsilateral inguinal lymph nodes with additional margins as described in the former passage.

The CTV should be trimmed to avoid bone, bowel, muscle and bladder.

ITV (internal target volume) should be identical to the CTV as organ movement can be neglected.

PTV (planning target volume) is defined according to the ICRU definition.

16.4.4 Organs at risk

The volumes of both kidneys should be outlined in each CT image. No more than 25% of each kidney volume should receive more than 20 Gy.

For radiotherapy of brain metastases see appendix [XI](#) and [XII](#).

17 Patient Information

The written information regarding treatment options must be given to all patients, with adequate time for remaining questions. Furthermore, both oral and written information should be given about the [registration in the SWENOTECA](#) database. Patients may opt out this registration. The patient should be treated and followed according to the same principles regardless of whether he consents to registration.

In Norway, the patients are requested to sign the written patient information, and the patients are registered at the university hospitals of Oslo, Bergen, Trondheim and Tromsø.

In Sweden this is done in the Swedish Testicular Cancer Register, which is an official National Quality Register, with SWENOTECA monitoring of the case records.

Immediately after the informed consent/opt out has been given, the SWENOTECA “Registreringsblankett” should be completed.

In Sweden: Each treating hospital is responsible for this registration.

18 Appendix

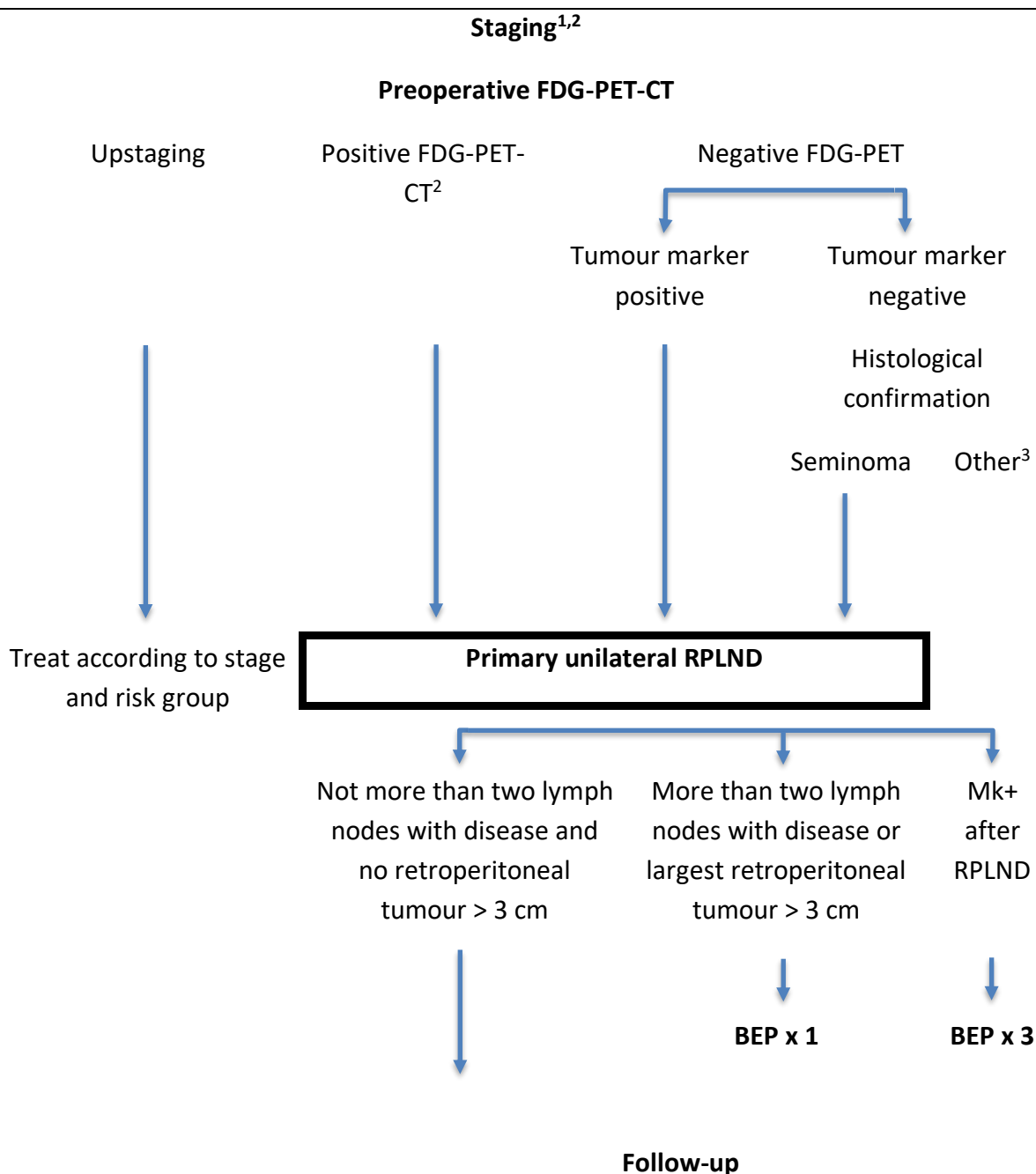
I. Prognostic risk group classification according to IGCCCG

<u>Nonseminoma</u>	<u>Seminoma</u>
<u>Good prognosis</u>	
Primary site: Testis or retroperitoneum <u>and</u> No non-pulmonary visceral metastases (for example liver, bone, brain) <u>and all</u> good markers β -hCG < 5000 IU/L (1000 µg/L) <u>and</u> AFP < 1000 µg/L <u>and</u> LDH < 1.5 x ULN	Any primary site <u>and</u> No non-pulmonary visceral metastases (for example liver, bone, brain) <u>and</u> any β -hCG, any LDH and normal AFP <i>LDH > 2.5 x ULN may imply a worse prognosis within the good prognosis group</i>
<u>Intermediate prognosis</u>	
Primary site: Testis or retroperitoneum <u>and</u> No non-pulmonary visceral metastases (for example liver, bone, brain) <u>and any</u> intermediate markers β -hCG \geq 5000 IU/L and \leq 50000 IU/L <u>or</u> AFP \geq 1000 and \leq 10000 µg/L <u>or</u> LDH \geq 1.5 x ULN \leq 10 x ULN	Non-pulmonary visceral metastases (for example liver, bone, brain)
<u>Poor prognosis</u>	
Mediastinal primary <u>or</u> Non-pulmonary visceral metastases (for example liver, bone, brain) <u>or any</u> poor markers β -hCG > 50000 IU/L) <u>or</u> AFP > 10000 µg/L <u>or</u> LDH > 10 x ULN	No seminoma with poor prognosis

II. Clinical staging according to Royal Marsden, modified

CS I	No evidence of metastases
CS Mk+	Tumour markers AFP/ β -hCG persistently elevated (not declining according to half-life), but no macroscopic metastatic disease demonstrated
CS II	Metastatic disease restricted to abdominal nodes: A Maximal transverse diameter <2 cm B Maximal transverse diameter 2–5 cm C Maximal transverse diameter >5–10 cm D Maximal transverse diameter >10 cm
CS III	Supradiaphragmatic node involvement For abdominal lymph-nodes: 0 : No metastases; A-D : According to CS II.
CS IV	Extra-lymphatic metastases For abdominal lymph-nodes: 0 : No metastases; A-D : According to CS II. H+ Liver metastases, Br+ Brain metastases, Bo+ Bone metastases

III. Flowchart RPLND Clinical Stage IIA-IIB (≤ 3 cm) Seminoma

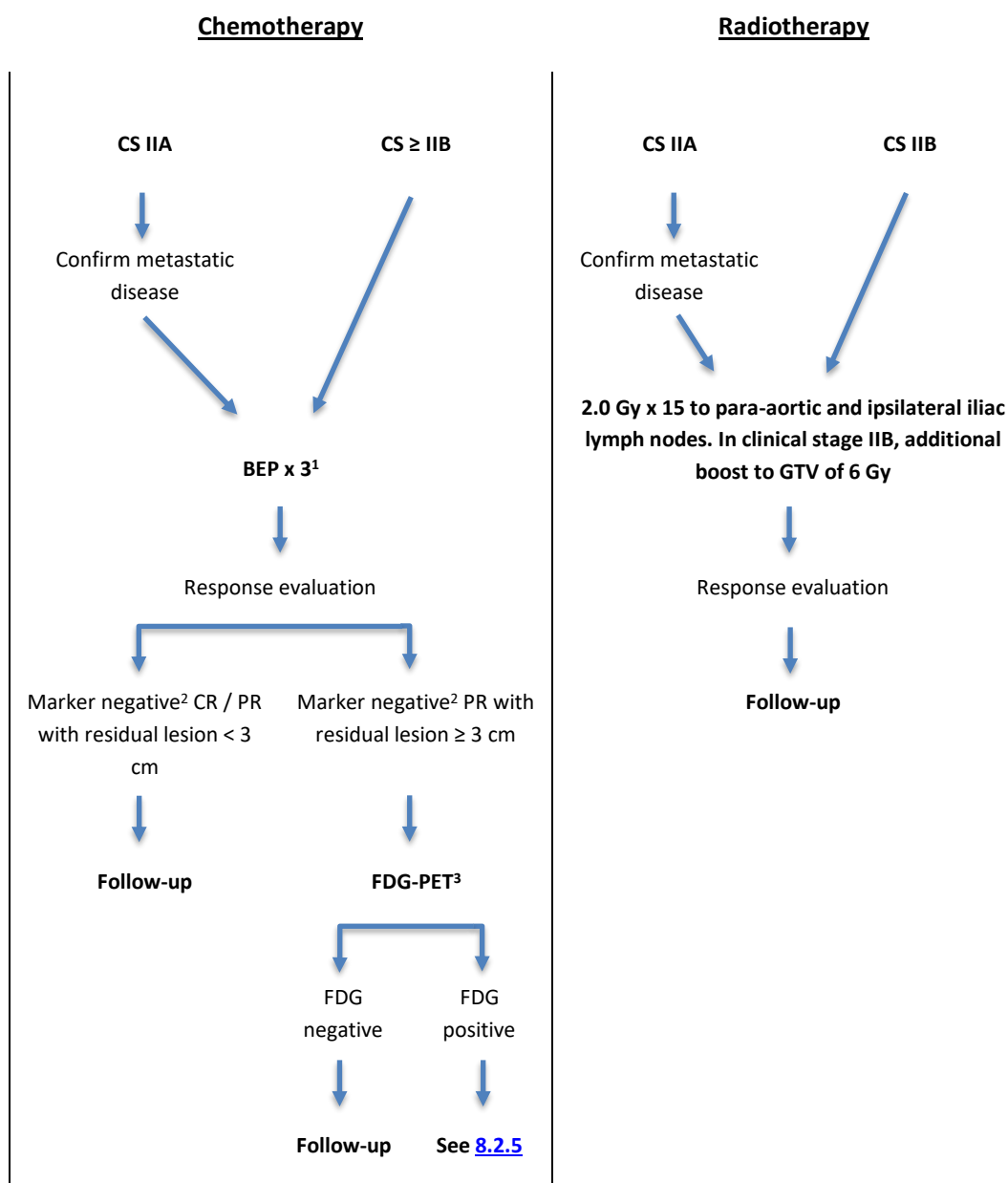


¹To properly stage patients in CS IIA, see [5.7.1](#)

²Not more than two lymph nodes or disease outside unilateral RPLND template

³Surveillance if benign, treat according to stage and risk group if nonseminoma

IV. Flowchart Metastatic Seminoma Good Prognosis, excluding Clinical Stage IIA-IIB (≤ 3 cm) suitable for surgery

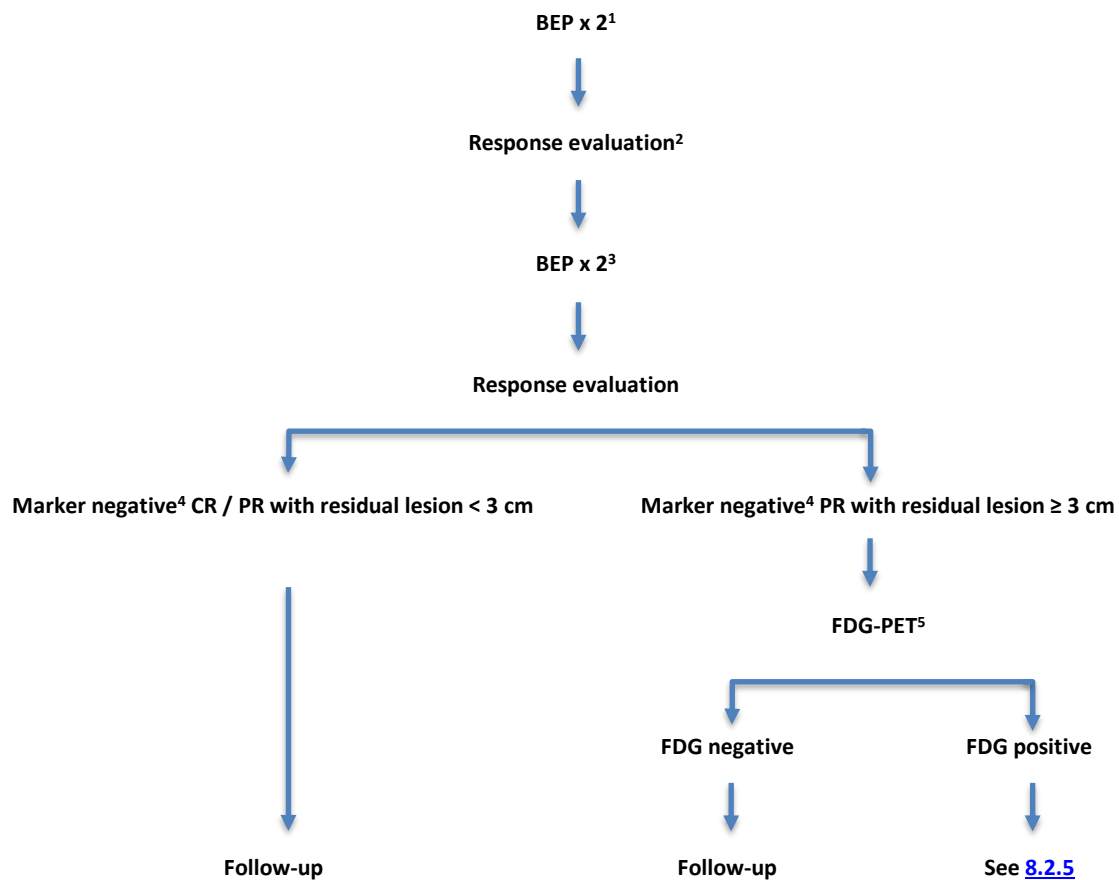


¹PEI x 3 or EP x 4 are optional treatment in case of contraindications to bleomycin. Evaluate with CT before third course.

²In case of positive markers after chemotherapy, discuss within SWENOTECA

³Not earlier than 9 weeks from day 1 of the last chemotherapy course

V. Flowchart Metastatic Seminoma Intermediate Prognosis



¹In patients with contraindications to bleomycin or brain metastasis PEI should be chosen

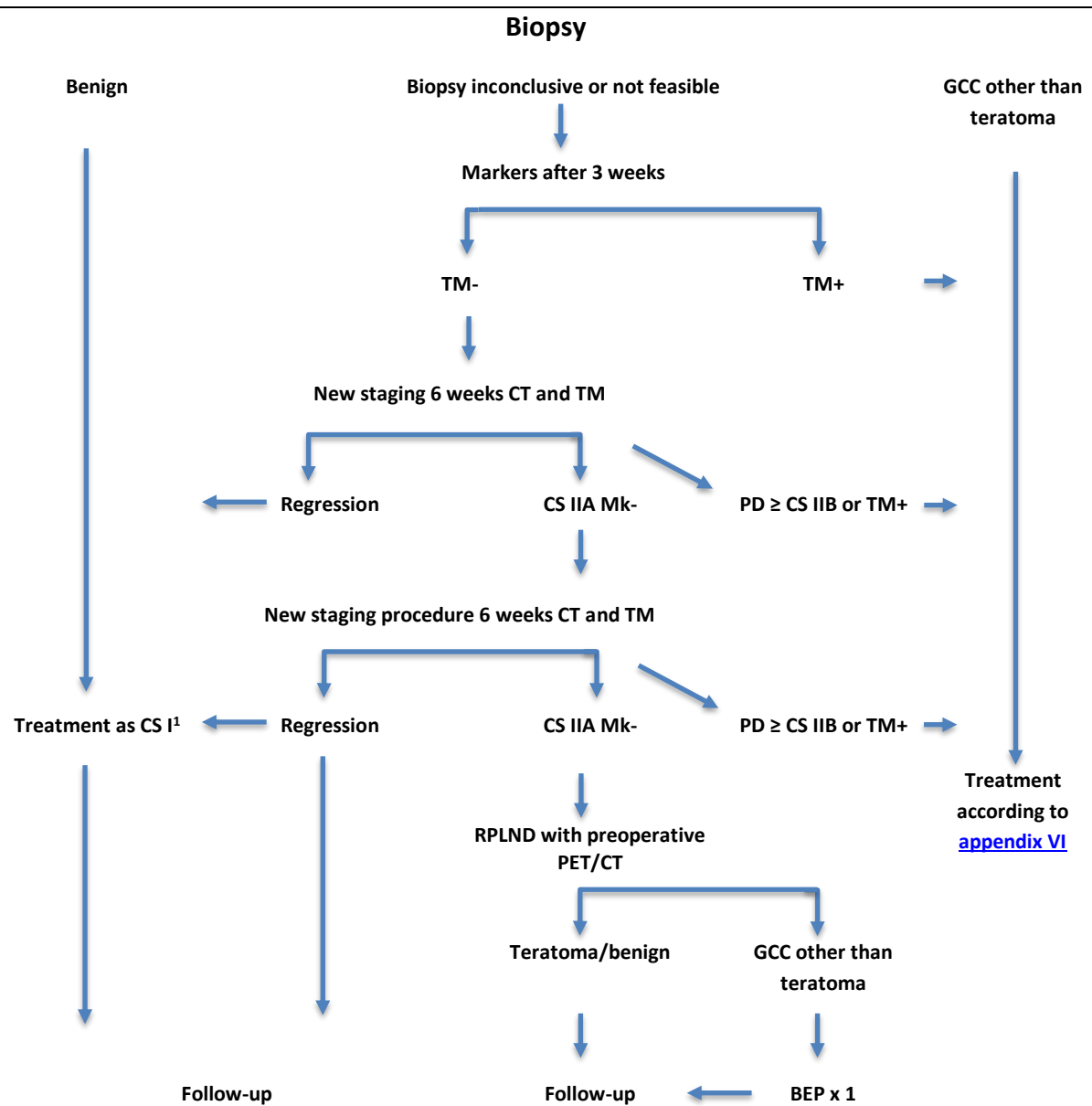
²In case of marker negative disease and lack of radiological response after two courses of chemotherapy, the possibility for teratoma should be considered and a biopsy should be performed

³Maximum cumulative dose of bleomycin is 300 000 units

⁴In case of positive markers after chemotherapy, discuss within SWENOTECA

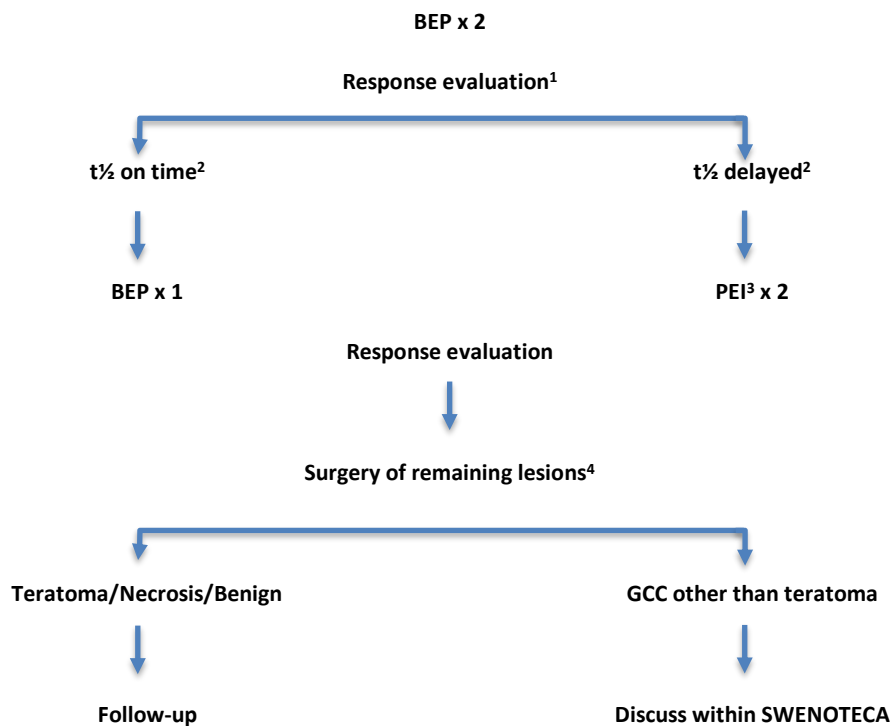
⁵Not earlier than 9 weeks from day 1 of the last chemotherapy course

VI. Flowchart Nonseminoma CS IIA Mk- at Diagnosis/Staging



¹Adjuvant chemotherapy not to be given later than 15 weeks after orchiectomy

VII. Flowchart Metastatic Nonseminoma Good Prognosis, excluding CS IIA Mk-



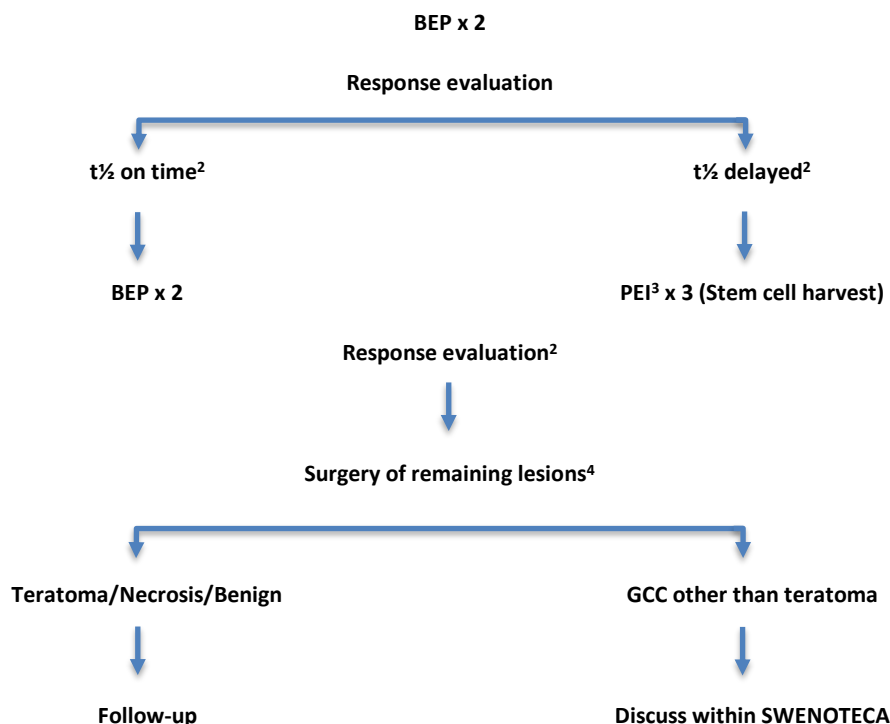
¹In patients without elevated markers before start of chemotherapy and radiological regression < 25% surgery should be considered in patients with predominately teratoma in the testicle

²Marker t½ on time: AFP ≤ 7 days, β-hCG ≤ 3 days, Marker t½ delayed: AFP > 7 days, β-hCG > 3 days; Marker progression: Re-evaluate for sanctuary metastasis (brain/bone) or new primary, consider surgery

³If initial treatment with PEI: Intensify to TIP

⁴Always surgery of remaining disease in nonseminoma if possible

VIII. Flowchart Metastatic Nonseminoma Intermediate and Poor Prognosis, excluding Non-pulmonary Visceral Metastasis or Primary Mediastinal Tumour ¹



¹**Intermediate prognosis markers:** AFP $\geq 1000 - 10\,000$ ng/ml or β -hCG $\geq 5000-50\,000$ IU/L or LDH $\geq 1.5 - 10$ x upper limit of normal; **Poor prognosis markers:** AFP $> 10\,000$ ng/ml or β -hCG $> 50\,000$ IU/L or LDH > 10 x upper limit of normal;

²t½ on time: AFP ≤ 7 days, β -hCG ≤ 3 days;

Marker t½ delayed: AFP > 7 days, β -hCG > 3 days;

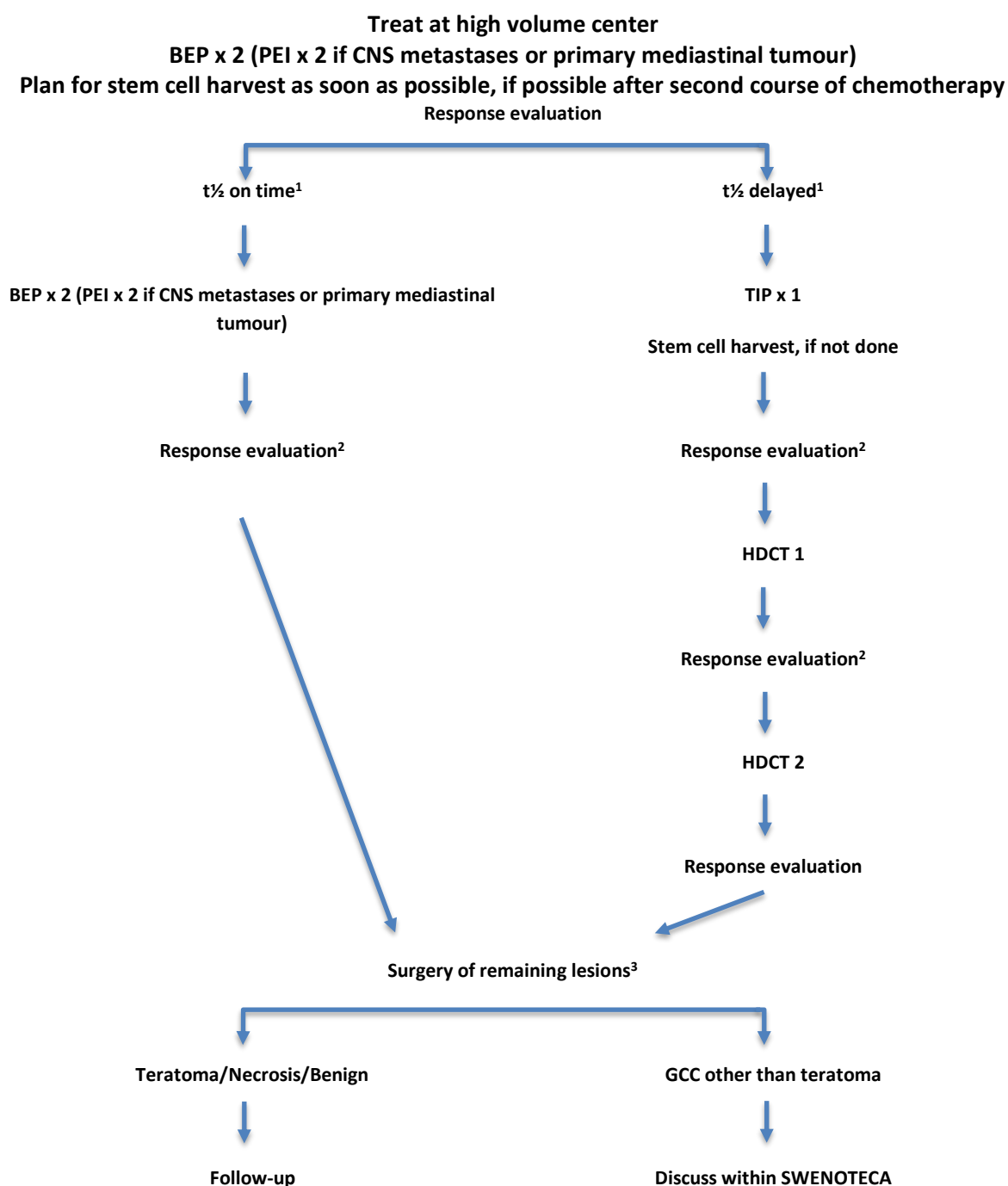
Marker progression: Re-evaluate for sanctuary metastasis (brain/bone) or new primary;

Progression: Discuss within SWENOTECA

³If initial treatment with PEI: Intensify to TIP

⁴Always surgery of remaining disease in nonseminoma if possible, also surgery in PR TM+ with declining/stable markers

IX. Flowchart Metastatic Nonseminoma Poor Prognosis with Non-pulmonary Visceral Metastasis or Primary Mediastinal Tumour

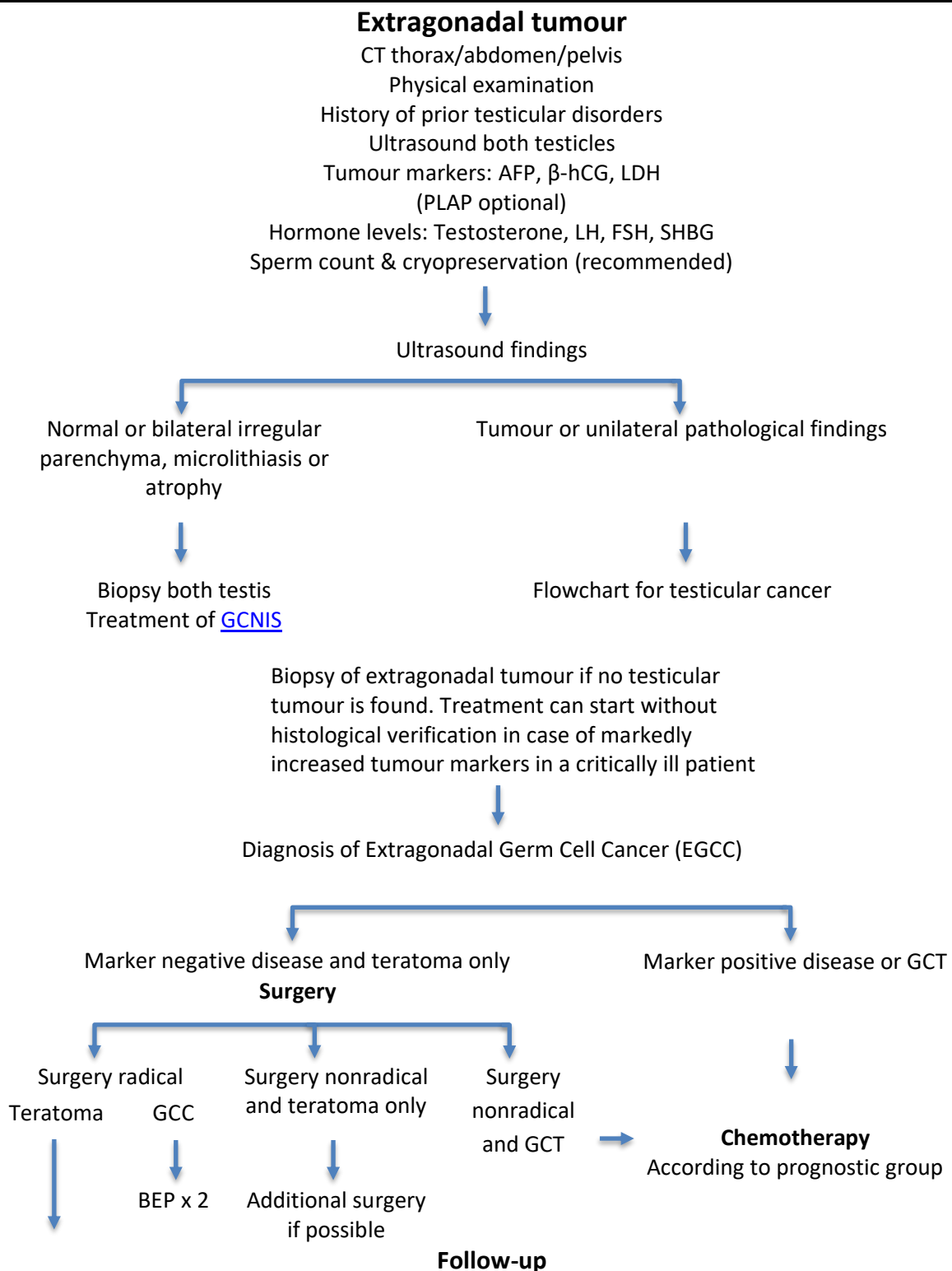


¹t½ on time: AFP ≤7 days, β-hCG ≤3 days; Marker t½ delayed: AFP >7 days, β-hCG >3 days; Marker progression: Re-evaluate for sanctuary metastasis (brain/bone) or new primary; Progression: Discuss within SWENOTECA

²Progression: Discuss within SWENOTECA

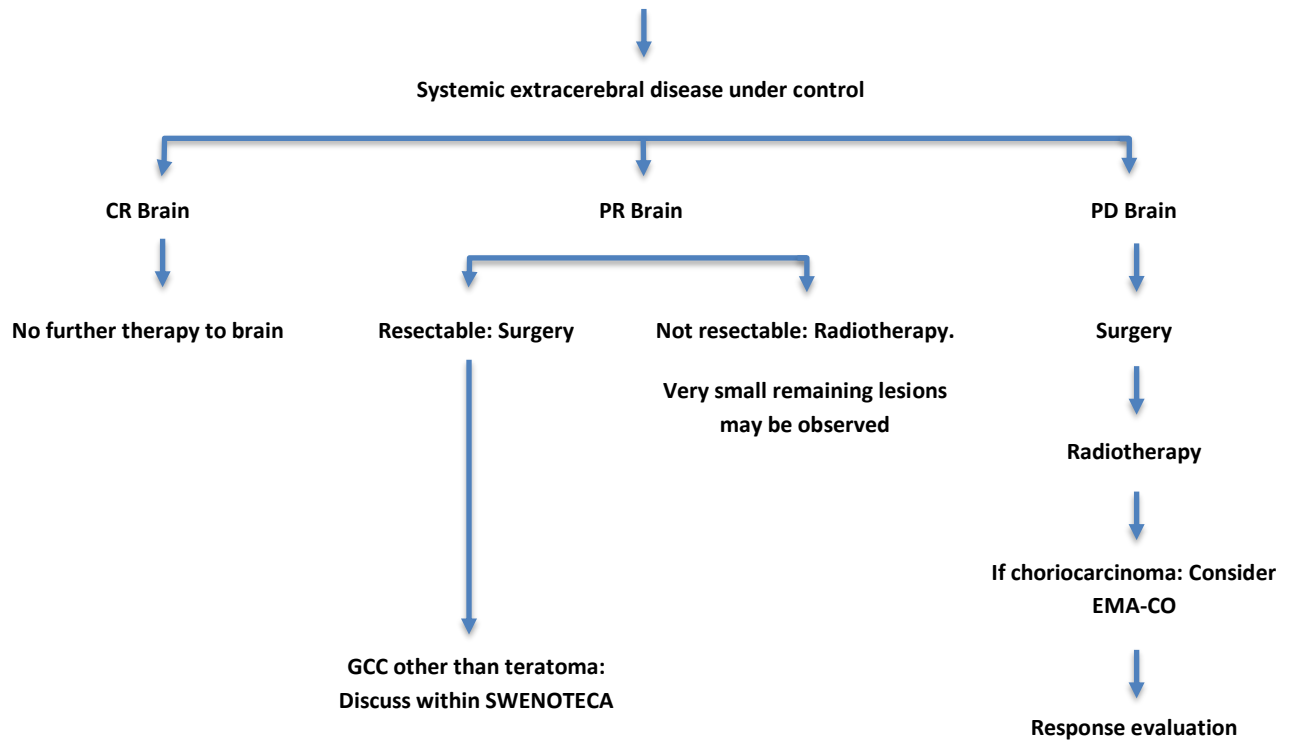
³Always surgery of remaining disease in nonseminoma if possible, also surgery in PR TM+ with declining/stable markers

X. Flowchart Extragenadal Germ Cell Tumours



XI. Flowchart Brain Metastases at Diagnosis

Chemotherapy according to poor prognosis with non-pulmonary visceral metastasis

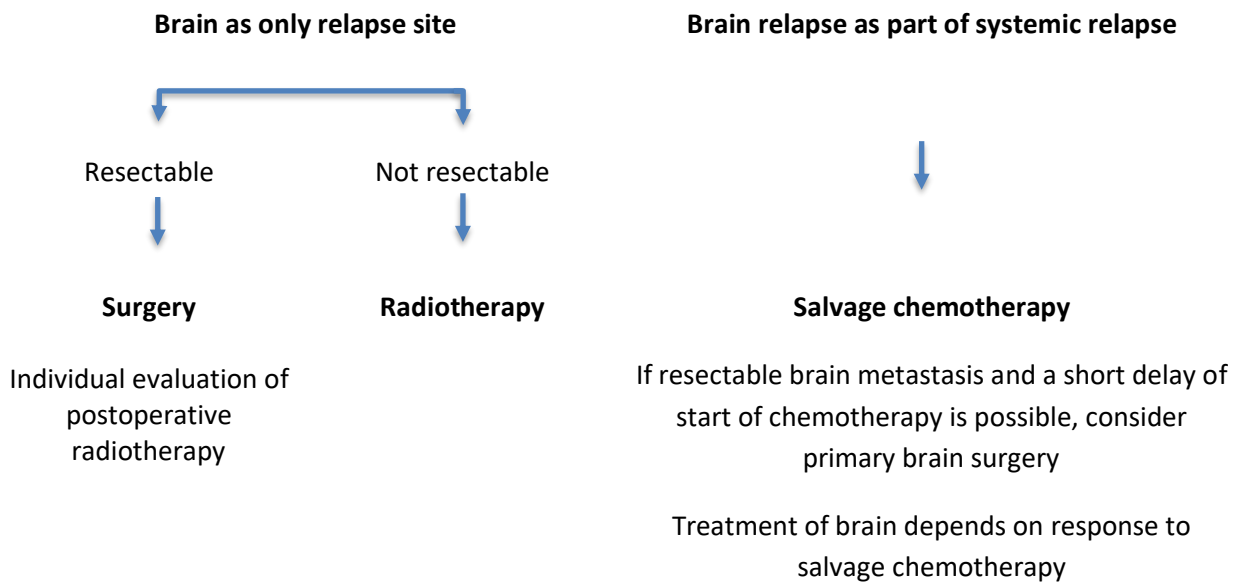


Radiotherapy

Whole brain irradiation: 1.8 Gy x 22 (total dose 39.6 Gy) with SIB 2.45 Gy x 22 (total dose 53.9 Gy).

Stereotactic irradiation: Few (max 4) and smaller metastases.

XII. Flowchart Brain Metastases at Relapse after CR

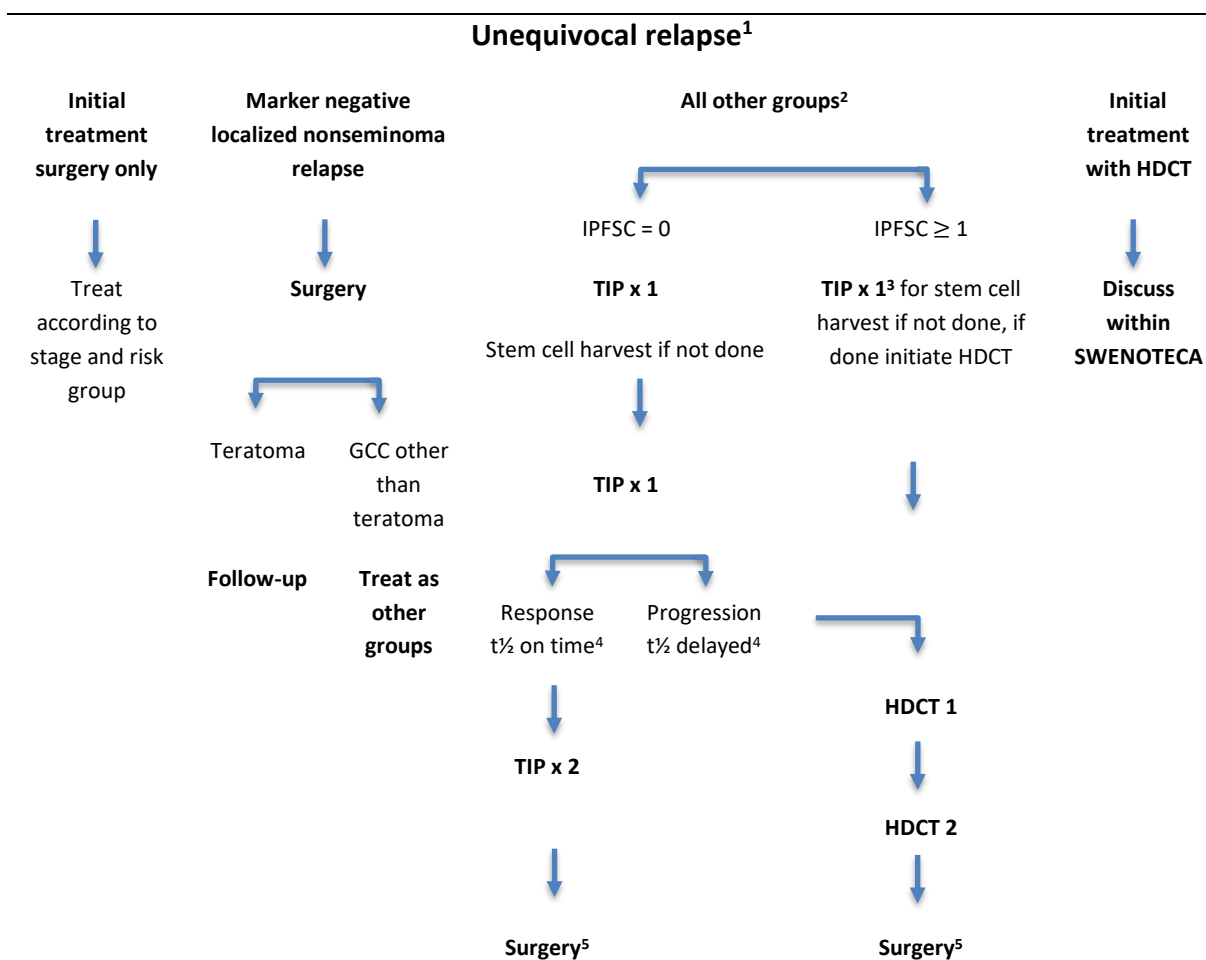


Radiotherapy

Whole brain irradiation: 1.8 Gy x 22 (total dose 39.6 Gy) with SIB 2.45 Gy x 22 (total dose 53.9 Gy).

Stereotactic irradiation: Few (max 4) and smaller metastases.

XIII. Flowchart Salvage Treatment Initial Metastatic Disease



¹Marker positive, biopsy verified or clinically unequivocal

²In small localized seminoma relapses radiotherapy may be a treatment option

³If the patient has received several courses of TIP as initial therapy other courses can be chosen as mobilization

⁴In nonseminoma

⁵Always surgery of remaining disease in nonseminoma if possible, in seminoma biopsy of PET positive or growing lesions (If vital cancer is found surgery should be the treatment of choice)

XIV. Follow-up schedule for seminoma patients

Name: _____ Civic registration number: _____
Orchiectomy, date: _____ Side: right / left Tumor size _____
Growth in rete testis: yes/no Date definitive staging: _____ Stage/prognostic group: _____
Date end of treatment: _____

This is a MINIMUM follow-up schedule.
FOLLOW-UP EVERY 3 MONTHS FOR INTERMEDIATE PROGNOSIS PATIENTS, AND PATIENTS WITH
RESIDUAL TUMORS YEAR 1.
Other examinations depending on primary metastatic locations, and/or any residual tumours

Control type **B**: Patient contact, AFP, β -hCG, LDH, S-creatinine, (PLAP optional), **MRI of the retroperitoneum/** (abdominopelvic CT).
Control type **C**: Like B with addition of clinical examination, testosterone, SHBG, LH, FSH. Chest X-ray for patients with primary metastatic disease.
Control type **TM**: Tumour markers, AFP, β -hCG and LDH, (PLAP optional). (*List the patient for a telephone appointment*)

Scrotal ultrasound when clinically indicated. Metabolic screening (lipids, fasting glucose, HbA1c), and blood pressure at 1-year and final visit. Inform Swedish patients at 1-, 5- and 10- year visit that a quality of life questionnaire will be sent out from RCC Syd, Sweden.

Months from end of latest treatment:

	B	C	
0	6	12	Follow-up year 1
	B	B	
12	18	24	Follow-up year 2
	TM	C	
24	30	36	Follow-up year 3
	TM	B	
36	42	48	Follow-up year 4
		C	
48		60	Follow-up year 5

Patients in CS I treated with RT: only abdominal imaging at the 2- and 5-year check-up.

Patients treated with carboplatin (CS I), and/or CS II-IV with residual tumours:

Year 7 from end of treatment: Check-up type B

Year 10 from end of treatment: Check-up type C

Patient care plan to be given to the patient at termination of follow-up

XV. Follow-up schedule for nonseminoma patients stage I, surveillance

Name: _____ Civic registration number: _____
 Orchiectomy, date: _____ Side: right / left LVI: yes/no
 Date definitive staging: _____ Recurrence date: _____ fill out new form and switch FU

TUMOR MARKERS SHOULD BE CHECKED EVERY 2 MONTHS YEAR 1 FOR PATIENTS WITH LVI+ MANAGED BY SURVEILLANCE

Control type **B**: Patient contact, AFP, β -hCG, LDH, S-creatinine, **MRI of the retroperitoneum/** (abdominopelvic CT).
 Control type **C**: Like B with addition of clinical examination, testosterone, SHBG, LH, FSH.
 Control type **TM**: Tumour markers, AFP, β -hCG and LDH (*List the patient for a telephone appointment*).

Scrotal ultrasound when clinically indicated. Metabolic screening (lipids, fasting glucose, HbA1c), and blood pressure at 1- and 5-year visit. Inform Swedish patients at 1- and 5- year visit that a quality of life questionnaire will be sent out from RCC Syd, Sweden.

Months from end of treatment:

	TM	B	TM	C	Follow-up year 1
0	3	6	9	12	
	TM	B	TM	B	Follow-up year 2
12	15	18	21	24	
		TM		C	Follow-up year 3
24		30		36	
		TM		B	Follow-up year 4
36		42		48	
		TM		C	Follow-up year 5
48		54		60	

Patient care plan to be given to the patient at termination of follow-up

Postpubertal teratoma: No TM check-up month 3, 9, 15, 21

XVI. Follow-up schedule for nonseminoma patients stage I, adjuvant BEP

Name: _____ Civic registration number: _____
 Orchiectomy, date: _____ Side: right / left LVI: yes/no
 Date definitive staging: _____ Recurrence date: _____ fill out new form and switch FU

Control type **B**: Patient contact, AFP, β -hCG, LDH, S-creatinine, **MRI of the retroperitoneum/** (abdominopelvic CT).

Control type **C**: Like B with addition of clinical examination, testosterone, SHBG, LH, FSH.

Control type **TM**: Tumour markers, AFP, β -hCG and LDH (*List the patient for a telephone appointment*).

Scrotal ultrasound when clinically indicated. Metabolic screening (lipids, fasting glucose, HbA1c), and blood pressure at 1- and 5-year visit. Inform Swedish patients at 1- and 5-year visit that a quality of life questionnaire will be sent out from RCC Syd, Sweden.

Months from end of treatment:

	TM	TM	TM	C	Follow-up year 1
0	3	6	9	12	
	TM	TM	TM	B	Follow-up year 2
12	15	18	21	24	
		TM		C	Follow-up year 3
24		30		36	
		TM		TM	Follow-up year 4
36		42		48	
		TM		C	Follow-up year 5
48		54		60	

Patient care plan to be given to the patient at termination of follow-up

XVII. Follow-up schedule for nonseminoma patients after treatment for metastatic or recurrent disease

Name: _____ Civic registration number: _____
 Orchiectomy, date: _____ Side: right / left LVI: yes/no Teratoma: in testis ☐ in metastases ☐ Date definitive staging: _____ Stage/prognostic group: _____ Date end of treatment: _____

This is a MINIMUM follow-up schedule
FOLLOW-UP EVERY 2 MONTHS FOR INTERMEDIATE AND POOR PROGNOSIS PATIENTS YEAR 1
Other examinations depending on primary metastatic locations, and/or any residual tumours

Control type **B**: Patient contact, AFP, β -hCG, LDH, S-creatinine, **MRI of the retroperitoneum/** (abdominopelvic CT) and pulmonary X-ray
 Control type **C**: Like B with addition of clinical examination, testosterone, SHBG, LH, FSH.
 Control type **TM**: Tumour markers, AFP, β -hCG and LDH. (List the patient for a telephone appointment)

Scrotal ultrasound when clinically indicated. Metabolic screening (lipids, fasting glucose, HbA1c), and blood pressure at 1-year and at last visit. Inform Swedish patients at 1-, 5- and 10- year visit that a quality of life questionnaire will be sent out from RCC Syd, Sweden.

Months from end of latest treatment:

	TM	B	TM	C	
0	3	6	9	12	Follow-up year 1
12	15	18	21	24	Follow-up year 2
24		30		36	Follow-up year 3
36		42		48	Follow-up year 4
48				60	Follow-up year 5

Patients in intermediate or poor prognosis group, all with residual tumors, all with teratoma in testis without RPLND, and all with teratoma in residual tumor resections:

Year 7 from end of treatment: Control type B

Year 10 from end of treatment: Control type C

For patients with multiple teratoma recurrences or inoperable residual tumours, lifelong follow-up may be indicated

Patient care plan to be given to the patient at termination of follow-up

XVIII. Patient care plan

Patient care plan to be delivered to the patient and general practitioner at termination of uro-oncological follow-up.

You were operated year: _____ for testicular cancer, subtype: ☐ Seminoma ☐ Non-seminoma

☐ No dissemination of disease

☐ Dissemination of disease to _____

Additional treatment

☐ No

☐ Chemotherapy (type and number of cycles: _____)

☐ Radiotherapy

☐ Surgery in addition to removal of the testicle _____

Date for last follow-up: _____ Hospital: _____

Responsible doctor: _____ Telephone: _____

You have completed the last oncological follow-up after previous treatment for testicular cancer. The risk for relapse of the disease is very low. This patient care plan should be shown in case of future contact with the health services.

You are at a slightly increased risk of a new tumour in the remaining testicle and regular self-exams are important. Men previously treated with chemotherapy and/or radiotherapy have an increased risk for hypertension, overweight, elevated cholesterol levels and cardiovascular disease. Thus, it is advisable to keep away from smoking, avoid overweight and exercise regularly. Further, a new cancer type may develop several years after treatment with chemotherapy and/or radiotherapy. We advise you to contact your general practitioner if you experience health problems in the future. You also have a risk of low levels of male sex hormones. Your sex hormone levels should be checked in case of loss of energy or lack of sexual interest/function.

Men treated with full chemotherapy or radiotherapy for metastatic disease are recommended to schedule regular check-ups (e.g every 2-5th year) at the general practitioner:

Blood pressure, height and weight

Blood samples including fasting lipids (total cholesterol, HDL and LDL-cholesterol, triglycerides), glucose, HbA1c, plus sex hormones (testosterone, SHBG, FSH and LH) if hypogonadal symptoms

Clinical examination in case of any symptoms

Initiate imaging or refer to a specialist in case of suspected relapse, second cancer or contralateral testicular cancer

The purpose of these controls is to prevent, identify and possibly treat complications of the previous cancer treatment. If abnormal values are detected at these controls, further follow-up at the general practitioner is initiated.

XIX. MRI Protocol

Recommended abdominal magnetic resonance imaging protocol for follow-up of patients with testicular cancer

General imaging protocol for 1.5T and 3T equipment. Examination is performed after a minimum of four hours fasting.

Besides a coronal localizer (preferably STIR or HASTE -based), transverse T2-weighted (preferably “conventional” TSE/FSE sequences or HASTE sequences depending on equipment) T1-weighted (preferably DIXON based 3D) pulse sequences with maximum 4 mm slice thickness and maximum 10% interslice gap from the diaphragm to the symphysis pubis are performed. The spatial resolution should be maximized with the specific equipment used.

Finally, transverse (multi-shot) EPI based DWI sequences with a maximum slice thickness of 6 mm are performed with the same coverage with b-values of 0 and 800 s/mm² and including an ADC map.

It is important that the examinations are performed and interpreted at institution with both expertise, a sufficient continuous number of abdominal MRIs as well as available of technologists and radiologists familiar with the relevant pattern of tumour recurrence in this group of patients to emphasize the appropriate aspects of the examination with respect both to preparation, acquisition and interpretation. It is important that the examinations are focused on the retroperitoneum since this is the major site of recurrence in this patient group.

MRI ABDOMEN SWENOTECA

SEQUENCE	STIR/HASTE Localiser	TSE/FSE	T1 spoiled gradient echo	T2/EPI b0_b800
WEIGHTING	T1 or 2	T2	T1	DWI
ORIENTATION	Cor	Ax	Ax	Ax
TR /TE (MS)	4-5000/82	4-6000/100	165/2 in opposed phase	5600/60
FIELD OF VIEW (MM)	480x275	320-400x275	320-400x275	320-400x275
MATRIX	256/128	512/215	256/136	192/156
THICKNESS/DST (MM)	5/1	Min	Min	5/1
NEX/NSA	1	1	1	4
NUMBER OF SECTIONS				
COVERAGE	Whole abdomen	Diaphragm-symphysis	Diaphragm-Symphysis	Diaphragm-symphysis
SCAN TIME (MIN:SEC)				

XX. BEP

BEP		Germ Cell Cancer	
<input type="checkbox"/> Preparat	Dos	Maxdos	Antal
<input type="checkbox"/>	dostillfälle	dostillfälle	doser/interv.
<input type="checkbox"/>	mg/m ²	mg	dygn tim cykel
1. Bleomycin*	300 000 IE**		1 3 im/iv inf 30 min
2. Etoposid	100		5 iv inf 2 tim 1-5
3. Cisplatin	20		5

☐ * då patienten erhållit en kumulativ dos bleomycin på 300 000 IE ges regimen utan bleomycin

☐ ** totaldos

<input type="checkbox"/> Prep	<input type="checkbox"/> 1	<input type="checkbox"/> 2	<input type="checkbox"/> 3	<input type="checkbox"/> 4	<input type="checkbox"/> 5	<input type="checkbox"/> 6	<input type="checkbox"/> 7	<input type="checkbox"/> 8	<input type="checkbox"/> 9	<input type="checkbox"/> 10	<input type="checkbox"/> 11	<input type="checkbox"/> 12	<input type="checkbox"/> 13	<input type="checkbox"/> 14	<input type="checkbox"/> 15	<input type="checkbox"/> 16	<input type="checkbox"/> 17	<input type="checkbox"/> 18	<input type="checkbox"/> 19	<input type="checkbox"/> 20	<input type="checkbox"/> 21	<input type="checkbox"/> 22	<input type="checkbox"/> 23	<input type="checkbox"/> 24	<input type="checkbox"/> 25	<input type="checkbox"/> 26	<input type="checkbox"/> 27	<input type="checkbox"/> 28	<input type="checkbox"/> 29	<input type="checkbox"/> 30	<input type="checkbox"/> 31	<input type="checkbox"/> 32	<input type="checkbox"/> 33	<input type="checkbox"/> 34	<input type="checkbox"/> 35	<input type="checkbox"/> 36	<input type="checkbox"/> 37	<input type="checkbox"/> 38	<input type="checkbox"/> 39	<input type="checkbox"/> 40	<input type="checkbox"/> 41	<input type="checkbox"/> 42	<input type="checkbox"/> 43	<input type="checkbox"/> 44	<input type="checkbox"/> 45	<input type="checkbox"/> 46	<input type="checkbox"/> 47	<input type="checkbox"/> 48	<input type="checkbox"/> 49	<input type="checkbox"/> 50	<input type="checkbox"/> 51	<input type="checkbox"/> 52	<input type="checkbox"/> 53	<input type="checkbox"/> 54	<input type="checkbox"/> 55	<input type="checkbox"/> 56	<input type="checkbox"/> 57	<input type="checkbox"/> 58	<input type="checkbox"/> 59	<input type="checkbox"/> 60	<input type="checkbox"/> 61	<input type="checkbox"/> 62	<input type="checkbox"/> 63	<input type="checkbox"/> 64	<input type="checkbox"/> 65	<input type="checkbox"/> 66	<input type="checkbox"/> 67	<input type="checkbox"/> 68	<input type="checkbox"/> 69	<input type="checkbox"/> 70	<input type="checkbox"/> 71	<input type="checkbox"/> 72	<input type="checkbox"/> 73	<input type="checkbox"/> 74	<input type="checkbox"/> 75	<input type="checkbox"/> 76	<input type="checkbox"/> 77	<input type="checkbox"/> 78	<input type="checkbox"/> 79	<input type="checkbox"/> 80	<input type="checkbox"/> 81	<input type="checkbox"/> 82	<input type="checkbox"/> 83	<input type="checkbox"/> 84	<input type="checkbox"/> 85	<input type="checkbox"/> 86	<input type="checkbox"/> 87	<input type="checkbox"/> 88	<input type="checkbox"/> 89	<input type="checkbox"/> 90	<input type="checkbox"/> 91	<input type="checkbox"/> 92	<input type="checkbox"/> 93	<input type="checkbox"/> 94	<input type="checkbox"/> 95	<input type="checkbox"/> 96	<input type="checkbox"/> 97	<input type="checkbox"/> 98	<input type="checkbox"/> 99	<input type="checkbox"/> 100
<input type="checkbox"/> 1	<input type="checkbox"/> 2	<input type="checkbox"/> 3	<input type="checkbox"/> 4	<input type="checkbox"/> 5	<input type="checkbox"/> 6	<input type="checkbox"/> 7	<input type="checkbox"/> 8	<input type="checkbox"/> 9	<input type="checkbox"/> 10	<input type="checkbox"/> 11	<input type="checkbox"/> 12	<input type="checkbox"/> 13	<input type="checkbox"/> 14	<input type="checkbox"/> 15	<input type="checkbox"/> 16	<input type="checkbox"/> 17	<input type="checkbox"/> 18	<input type="checkbox"/> 19	<input type="checkbox"/> 20	<input type="checkbox"/> 21	<input type="checkbox"/> 22	<input type="checkbox"/> 23	<input type="checkbox"/> 24	<input type="checkbox"/> 25	<input type="checkbox"/> 26	<input type="checkbox"/> 27	<input type="checkbox"/> 28	<input type="checkbox"/> 29	<input type="checkbox"/> 30	<input type="checkbox"/> 31	<input type="checkbox"/> 32	<input type="checkbox"/> 33	<input type="checkbox"/> 34	<input type="checkbox"/> 35	<input type="checkbox"/> 36	<input type="checkbox"/> 37	<input type="checkbox"/> 38	<input type="checkbox"/> 39	<input type="checkbox"/> 40	<input type="checkbox"/> 41	<input type="checkbox"/> 42	<input type="checkbox"/> 43	<input type="checkbox"/> 44	<input type="checkbox"/> 45	<input type="checkbox"/> 46	<input type="checkbox"/> 47	<input type="checkbox"/> 48	<input type="checkbox"/> 49	<input type="checkbox"/> 50	<input type="checkbox"/> 51	<input type="checkbox"/> 52	<input type="checkbox"/> 53	<input type="checkbox"/> 54	<input type="checkbox"/> 55	<input type="checkbox"/> 56	<input type="checkbox"/> 57	<input type="checkbox"/> 58	<input type="checkbox"/> 59	<input type="checkbox"/> 60	<input type="checkbox"/> 61	<input type="checkbox"/> 62	<input type="checkbox"/> 63	<input type="checkbox"/> 64	<input type="checkbox"/> 65	<input type="checkbox"/> 66	<input type="checkbox"/> 67	<input type="checkbox"/> 68	<input type="checkbox"/> 69	<input type="checkbox"/> 70	<input type="checkbox"/> 71	<input type="checkbox"/> 72	<input type="checkbox"/> 73	<input type="checkbox"/> 74	<input type="checkbox"/> 75	<input type="checkbox"/> 76	<input type="checkbox"/> 77	<input type="checkbox"/> 78	<input type="checkbox"/> 79	<input type="checkbox"/> 80	<input type="checkbox"/> 81	<input type="checkbox"/> 82	<input type="checkbox"/> 83	<input type="checkbox"/> 84	<input type="checkbox"/> 85	<input type="checkbox"/> 86	<input type="checkbox"/> 87	<input type="checkbox"/> 88	<input type="checkbox"/> 89	<input type="checkbox"/> 90	<input type="checkbox"/> 91	<input type="checkbox"/> 92	<input type="checkbox"/> 93	<input type="checkbox"/> 94	<input type="checkbox"/> 95	<input type="checkbox"/> 96	<input type="checkbox"/> 97	<input type="checkbox"/> 98	<input type="checkbox"/> 99	<input type="checkbox"/> 100	

☐ Dag ☐ 1 ☐ 2 ☐ 3 ☐ 4 ☐ 5 ☐ 6 ☐ 7 ☐ 8 ☐ 9 ☐ 10 ☐ 11 ☐ 12 ☐ 13 ☐ 14 ☐ 15 ☐ 16 ☐ 17 ☐ 18 ☐ 19 ☐ 20 ☐ 21 ☐ 22 ☐ 23 ☐ 24 ☐ 25 ☐ 26 ☐ 27 ☐ 28 ☐ 29 ☐ 30 ☐ 31 ☐ 32 ☐ 33 ☐ 34 ☐ 35 ☐ 36 ☐ 37 ☐ 38 ☐ 39 ☐ 40 ☐ 41 ☐ 42 ☐ 43 ☐ 44 ☐ 45 ☐ 46 ☐ 47 ☐ 48 ☐ 49 ☐ 50 ☐ 51 ☐ 52 ☐ 53 ☐ 54 ☐ 55 ☐ 56 ☐ 57 ☐ 58 ☐ 59 ☐ 60 ☐ 61 ☐ 62 ☐ 63 ☐ 64 ☐ 65 ☐ 66 ☐ 67 ☐ 68 ☐ 69 ☐ 70 ☐ 71 ☐ 72 ☐ 73 ☐ 74 ☐ 75 ☐ 76 ☐ 77 ☐ 78 ☐ 79 ☐ 80 ☐ 81 ☐ 82 ☐ 83 ☐ 84 ☐ 85 ☐ 86 ☐ 87 ☐ 88 ☐ 89 ☐ 90 ☐ 91 ☐ 92 ☐ 93 ☐ 94 ☐ 95 ☐ 9

Speciella åtgärder

Cisplatin: S-kreatinin inför varje cykelstart. Om patologiskt utföres iohexol-clearance. Cisplatin ges med forcerad diures.

CAVE! aminoglykosid skall ej givas under eller en månad efter cisplatinbehandling.

Bleomycin: om toxisk reaktion vid bleomycintillförel (feber, frossa) ges steroider exempelvis Deltison 25 mg po eller 3–4 mg Betapred. Försättningsvis ges steroider profylaktiskt före bleomycin.

Dosreduktionsrekommendationer

Benmärgstøxicitet ☒ ☐

Neutrofil $\times 10^9/L$	TPK $\times 10^9/L$	Preparat, % av totaldos	Åtgärd
		1 2 3	
$> 0,5$ och $< 1,0$	50	100 100 100	Ge behandling. G-CSF enligt lokala riktlinjer. OBS! – om TPK cirka 50 skall nadir ha passerats!
$< 0,5$	50		Behandling uppskjutes i högst 3 dagar. Behandling kan dock ges följt av G-CSF om situationen så kräver!
< 50			Βενονδάνγεν υπακούεσιν ΤΡΚ 50.

Nedatturfunksjon*

Korrigerat iohexolclearance (ml/min/1.73 m²), normalvärde 80–125 för 18–50 år.

50–59	100	100	100	Cisplatin ges endast i 4 dagar
40–49	50	100	100	Cisplatin ges endast i 3 dagar
< 40	0	100	**	Cisplatin ersätts med Karboplatin doserat efter Calverts formel AUC 7**

Korrigerat iohexolclearance (ml/min/ 1,73 m²), normalvärde 60–110 för 51–65 år.

40-49	50	100	100	Cisplatin ges endast i 4 dagar
< 40	0	100	**	Cisplatin ersätts med Karboplatin doserat efter Calverts formel AUC 7**

***Dock, om nedsatt njurfunktion beror på tumörobstruktion skall fulldos Cisplatin ges. Nefrostomi kan behövas.**

** Totaldos Karboplatin, mg = 7 x (okorrigerat clearance ml/min + 25). Karboplatin gives endast dag 1!

Anmärkning

Bleomycin: CAVE! Risk för allvarlig pneumonit föreligger. Var observant på tecken på pneumonit. Ökad risk vid hög ackumulerad totaldos, nedsatt njurfunktion, äldre patienter, hög O₂-koncentration i inandningsluft, tidigare eller samtidig strålbehandling mot thorax.

BEP

Blandning och administrering

Preparat	Blandas i ml	Administrering		Sköljdropp NaCl, ml	Spoldropp NaCl, ml	Kemiskt stabil	Kommentar
		sätt	tid				
Cisplatin	1000 NaCl	iv inf	2 tim	250		72 tim rumstemp	
Etoposid							
Bleomycin	250 NaCl	iv inf	30 min			7 dygn, kallt	

Prehydrering:

1 000 NaCl under 2 tim.

Hydrering under behandlingen:

Under behandlingsdygnet ges ytterligare minst 2 000 ml vätska po el iv .

Posthydrering:

Dygnet efter sista cisplatininfusion minst 2 000 ml; om patienten ej själv kan dricka denna mängd, skall vätska givas iv.

Diuresen under behandlingsdygnet samt dygnet efter sista cisplatinbehandlingen skall vara > 400 ml/4 tim. Mätning startar samtidigt med start av prehydrering.

XXI. EP

[illegible]

Speciella åtgärder

Cisplatin: S-kreatinin inför varje cykelstart. Om patologiskt utföres iohexol-clearance. Cisplatin ges med forcerad diures. **CAVE!** aminoglykosid skall ej givas under eller en månad efter cisplatinbehandling.

Dosreduktionsrekommendationer ☐

Benmärgstoxicitet	TPK $\times 10^9/L$	Preparat, % av full dos	Åtgärd
Neutrofil $\times 10^9/L$		1 2	
$> 0,5$ och $< 1,0$	50	100 100	Ge behandling. G-CSF enligt lokala riktlinjer. OBS! – om TPK cirka 50 skall nadir ha passerats!
$< 0,5$	50		Behandling uppskjutes i högst 3 dagar. Behandling kan dock ges följt av G-CSF om situationen så kräver!
	< 50		Behandling uppskjutes i högst 3 dagar. TTK < 50 .

Nedatturfunksjon*

Korrigerat iohexolclearance (ml/min/1.73 m²), normalvärde 80–125 för 18–50 år.

50–59	100	100	Cisplatin ges endast i 4 dagar
40–49	100	100	Cisplatin ges endast i 3 dagar
< 40	100	**	Cisplatin ersätts med Karboplatin doserat efter Calverts formel AUC 7**

Korrigerat iohexolclearance (ml/min/ 1.73 m²), normalvärde 60–110 för 51–65 år.

40–49	100	100	Cisplatin ges endast i 4 dagar
< 40	100	**	Cisplatin ersätts med Karboplatin doserat efter Calverts formel AUC 7**

***Dock, om nedsatt njurfunktion beror på tumörobsstruktion skall fulldos Cisplatin ges. Nefrostomi kan behövas.**

** Totaldos Karboplatin, mg = 7 x (okorrigerat clearance ml/min + 25). Karboplatin gives endast dag 1!

Anmärkning

EP

Blandning och administrering

Preparat	Blandas i ml	Administrering sätt	tid	Sköljdropp NaCl, ml	Spoldropp NaCl, ml	Kemiskt stabil	Kommentar
250							
Cisplatin	1000 NaCl	iv inf	2 tim			72 tim rumstemp	
Etoposid							

Prehydrering:

1000 NaCl under 2 tim.

Hydrering under behandlingen:

Under behandlingsdygnet ges ytterligare minst 2 000 ml vätska po el iv .

Posthydrering:

Dygnet efter sista cisplatininfusion minst 2 000 ml; om patienten ej själv kan dricka denna mängd, skall vätska givas iv.

Diuresen under behandlingsdygnet samt dygnet efter sista cisplatinbehandlingen skall vara > 400 ml/4 tim. Mätning startar samtidigt med start av prehydrering.

XXII. Carboplatin

Karboplatin				Seminom, adjuvant behandling			
Preparat	Dos/ dostillfälle mg/m ²	Maxdos/ dostillfälle mg	Antal doser/ dygn	Dos interv. tim	Antal doser/ cykel	Administreringssätt	Dag
1. Karboplatin	7×(GFR+25)*		1		1	iv inf 30 min	1
*totaldos							
Calverts formel: Dos = AUC x (GFR + 25)							
AUC = 7 mg/ml × min							
GFR = ml/min, okorrigerat värde							
Dos = mg, totaldos							
Prep 1	1					Ny cykel	
Dag	1					22	
Cykellängd: 21 d							
Beredning och administrering v g v							

Speciella åtgärder

Iohexolclearance för beräkning av GFR före behandlingsstart. S-kreatinin före varje cykel.
Om s-kreatinin stiger >20 % göres iohexolclearance.

Dosreduktionsrekommendationer

Vid cykelstart:

<1.0

<100

Preparat, % av fulldos

1

Behandlingen uppskjutes

Anmärkning

Karboplatin

Seminom, adjuvant behandling

Preparat	Dos/ dostillfälle mg/m ²	Maxdos/ dostillfälle mg	Antal doser/ dygn	Dos interv. tim	Antal doser/ cykel	Administreringssätt	Dag
1. Karboplatin	7×(GFR+25)*		1		1	iv inf 30 min	1
*totaldos							
Calverts formel: Dos = AUC x (GFR + 25)							
AUC = 7 mg/ml × min							
GFR = ml/min, okorrigerat värde							
Dos = mg, totaldos							
Prep	1					Ny cykel	
Dag	1						22

Cykellängd: 21 d

Beredning och administrering v g v

Speciella åtgärder

Iohexolclearance för beräkning av GFR före behandlingsstart. S-kreatinin före varje cykel.
Om s-kreatinin stiger >20 % göres iohexolclearance.

Dosreduktionsrekommendationer

Granulocyter × 10⁹/L TPK × 10⁹/L

Vid cykelstart:

<1.0

<100

Preparat, % av fulldos

1

Behandlingen uppskjutes

Anmärkning

XXIII. TIP

Germ Cell Cancer

Preparat	Dos dostillfälle mg/m ²	Maxdos dostillfälle mg	Antal doser/ dygn	Dos interv. tim	Antal doser/ cykel	Administreringsätt	Dag
1. Paclitaxel	250		1		1	iv inf 24 tim	1
2. Etoposid	1500		1		4	iv inf 2 tim	2-5
3. Mesna	300		1		4		
Mesna*	300		2		8	iv inj 4 och 8 tim efter avslutad Etoposidinf	
4. Cisplatin	25		1		4	iv inf 2 tim	2-5

*Mesna: Kan även ges peroralt den 2:a dubbel dos (40 % av Etoposiddosen). Första dosen ges tillsammans med Etoposid, de följande perorala doserna 2 och 8 tim efter avslutad Etoposidinf.

Prep
 1 1
 2 2 2 2
 3 3 3 3
 4 4 4 4
 0 0

Cykellängd: 21 d

Beredning och administrering v g v

Speciella åtgärder

Paclitaxel premedicinering: 30 min före start av infusion gives inj. Betametason 12 mg iv, inj. Clemastin 2 mg iv, inj Ranitidin 50 mg iv.

Kontroll av puls och blodtryck före och 15 min efter start av infusion.

Ακτινολογικά + ΠΜ φ/ρ ΣΥΓΓΡΕΨΕΤΕ ΔΟΚΙΜΙΑ ΜΕΡΙΚΑ ΡΕΑΚΤΙΒΑ ΚΑΙ ΠΑΡΑΛΛΗΛΗ ΓΙΑ ΑΤΚ ΚΑΙ ΣΚΟΛΗΝΟΣ ΕΒΑΡ ΠΣ ΠΕΡΑΝ ΣΚΟΛΕ.
Se även "Handläggning av lindrig reaktion vid Taxolinfusion".

Cisplatin: S-kreatinin inför varje cykelstart. Om patologiskt utföres iohexol-clearance. Cisplatin ges med forcerad diures.

CAVE! aminoglykosid skall ej givas under eller en månad efter cisplatinbehandling.

G-CSF: 5 $\mu\text{g/kg}$ gives från och med dag 7.

Ifosfamid: Observerans på cystitbesvär. Hematuristicka vid behov. Om 3+ så avbryts ifosfamidbehandlingen.

Dosreduktionsrekommendationer

Benmärgstoxicitet ☒ ☐

Preparat, dos och frekvens	Åtgärd
<input type="checkbox"/> 0,5 eller <input type="checkbox"/> 50 < 0,5 eller < 50	OBS! – om TPK cirka 50 skall nadir ha passerats! Behandling uppskjutes kortast möjliga tid.

Nedatturfunksjon*

Korrigerat iohexolclearance (ml/min/1,73 m²), normalvärde 80–125 för 18–50 år.

50-59	100	100	80	Dag 2-5
40-49	100	100	80	Dag 2-4
< 40	100	100	**	Cisplatin ersätts med Karboplatin doserat efter Calverts formel AUC 7**

Korrigerat iohexolclearance (ml/min/ 1,73 m²), normalvärde 60–110 för 51–65 år.

40-49	100	100	80	Dag 2-5
< 40	100	100	**	Cisplatin ersätts med Karboplatin doserat efter Calverts formel AUC 7**

***Dock, om nedsatt njurfunktion beror på tumörobstruktion skall fulldos Cisplatin ges. Nefrostomi kan behövas.**

** Totaldos Karboplatin, mg = 7 x (okorrigerat clearance ml/min + 25). Karboplatin gives endast dag 1!

Anmärkning

TIP Ø Østikercancer

Blandning och administrering

Preparat	Blandas i ml	Administrering sätt	Administrering tid	Skölldropp NaCl, ml	Spoldropp NaCl, ml	Kemiskt stabil	Kommentar
Paclitaxel	1000 NaCl	iv inf	24 tim	250			48 tim, rumstemp
Ifosfamid	1000 NaCl	iv inf	2 tim	250			72 tim, kallt
Mesna 1:a dos							
Mesna följande doser		iv inj/po					
Cisplatin	1000 NaCl	iv inf	2 tim				72 tim, rumstemp

Prehydrering:

1 000 NaCl under 2 tim.

Hydrering under behandlingen:

Under behandlingsdygnet gives ytterligare minst 2 000 ml vätska po el iv .

Posthydrering:

Dygnet efter sista cisplatininfusion minst 2 000 ml; om patienten ej själv kan dricka denna mängd, skall vätska givas iv.

Diuresen under behandlingsdygnet samt dygnet efter sista cisplatinbehandlingen skall vara > 400 ml/4 tim. Mätning startar samtidigt med start av prehydrering.

PEI

Blandning och administrering

Preparat	Blandas i ml	Administrering sätt	tid	Sköljdropp NaCl, ml	Spoldropp NaCl, ml	Kemiskt stabil	Kommentar
Cisplatin	1000 NaCl	iv inf	2 tim	250			72 tim rumstemp
Etoposid							
Ifosfamid	250 NaCl	iv inf	30 min				72 tim, kallt
Mesna 1:a dos							
Mesna dos 2 och 3 gives om möjligt po							

Prehydrering:

1 000 NaCl under 2 tim.

Hydrering under behandlingen:

Under behandlingsdygnet gives ytterligare minst 2 000 ml vätska po el iv.

Posthydrering:

Dygnet efter sista cisplatininfusion minst 2 000 ml; om patienten ej själv kan dricka denna mängd, skall vätska givas iv.

Diuresen under behandlingsdygnet samt dygnet efter sista cisplatinbehandlingen skall vara > 400 ml/4 tim. Mätning startar samtidigt med start av prehydrering.

XXV. GOP

2012 05 07/ES

GOP		Germ cell cancer						
Preparat		Dos/ dostillfälle mg/m ²	Maxdos/ dostillfälle mg	Antal doser/ dygn	Dos interv. tim	Antal doser/ cykel	Administreringssätt	Dag
1. Gemcitabin		800		1		2	iv inf 30 min	1 + 8
2. Oxaliplatin		130		1		1	iv inf 2 tim	1
3. Paclitaxel		80		1		2	iv inf 1 tim	1 + 8

Prep								
1	1		1					
2	2							
3	3		3					

						Ny cykel		
						↓		
Dag	1		8					22

Cykellängd: 21 d
Beredning och administrering v g v

Speciella åtgärder

Oxaliplatin: Vid polyneuropati gives substitution med calcium och magnesium (se omstående sida).

Paclitaxel premedicinering: 30 min före infusion gives inj Betametason 6 mg iv. Gives endast dag 1 och 8 i cykel 1 om inga oönskade reaktioner inträffat. Inj. Clemastin 2 mg iv inj. Ranitidin 50 mg iv gives samtliga cykler.

Kontroll av puls och blodtryck före och 15 min efter start av infusion dag 1 och 8 cykel 1.

Akutbricka + PM för åtgärder vid akuta allergiska reaktioner skall vara tillgängliga. Läkare skall finnas nåbar på personsökare. Se även "Handläggning av lindrig reaktion vid Taxolinfusion".

Dosreduktionsrekommendationer		Preparat, % av fulldos dag 1			Preparat, % av fulldos dag 8	
Granulocyter × 10 ⁹ /L	TPK × 10 ⁹ /L	1	2	3	1	3
≥ 1,0 och < 1,5	≥ 50 och < 75	100	100	100	75	75
≥ 0,5 och < 1,0	≥ 50	75	75	75	50	50
< 0,5	< 50	Behandlingen uppskjutes.				

G-CSF gives enligt lokala riktlinjer.

Om bestående neuropati WHO grad 2 (svåra parestesier och/eller lätt svaghet), dosreduceras oxaliplatin och paclitaxel till 75 % i följande cykler. Om grad 3–4 toxicitet gives inte denna behandling.

GOP

Blandning och administrering

Preparat	Blandas i ml	Administrering		Sköljdropp NaCl, ml	Spoldropp NaCl, ml	Kemiskt stabil	Kommentar
		sätt	tid				
500 5 % glukos							
Gemcitabin	250 NaCl	iv inf	30 min			72 tim rumstemp	
Oxaliplatin	500 5 % glukos	iv inf	1 tim			48 tim kallt	Inkompatibelt med NaCl
Paclitaxel	250 NaCl	iv inf	1 tim			48 tim rumstemp	Konc < 1,2 mg/ml ej PVC

2012-05-07/20

EMA-CO

Recidiv av HCG producerande germ cell cancer

Preparat	Dos/ dostillfälle mg/m ²	Maxdos/ dostillfälle mg	Antal doser/ dygn	Dos interv. tim	Antal doser/ cykel	Administreringssätt	Dag
1. Etoposid	100		1		2	iv inf	1 tim 1, 2
2. Daktinomycin	0.5*		1		2	iv inf	30 min 1, 2
3. Metotrexat	100		1		1	iv inf	30 min 1
4. Metotrexat	200		1		1	iv inf	12 tim 1
5. Kalciumfolinat	15*		4		8	po/iv	var 6:e tim 2, 3 med start 24 tim efter start av MTX
6. Vinkristin	1.0	2.0	1		1	iv inf	30 min 8
7. Cyklofosfamid	600		1		1	iv inf	30 min 8

*totaldos

Prep

1	1	1
2	2	2
3	3	
4	4	
5	5	5
6	6	
7	7	

Ny cykel
↓

Dag	1	2	3	8	15
-----	---	---	---	---	----

Cykellängd: 14 d

Beredning och administrering v g v

Speciella åtgärder

OBS! cykelintervallet skall ej överstiga 15 dagar.

Nedsatt njurfunktion, pleuravätska, ascites är relativa kontraindikationer för Mtx. Om det trots detta gives bör plasmakoncentrationen följas; förlängd kalciumfolinatrescue kan vara aktuell. Pat skall ha skriftliga instruktioner angående kalciumfolinatrescue. S-kreatinin följes under behandlingen.

Dosreduktionsrekommendationer

Granulocyter × 10 ⁹ /L	TPK × 10 ⁹ /L	Preparat, % av fulldos						
		1	2	3	4	5	6	7
<1.0	<100	75	100	100	100	100	100	75

Om även efter dosreduktion granulocyter <1.0 eller TPK × 10⁹/L <100 vid cykelstart gives i fortsättningen:

50	100	100	100	100	100	100	50
----	-----	-----	-----	-----	-----	-----	----

Anmärkning

EMA-CO

Blandning och administrering

Preparat	Blandas i ml	Administrering sätt	Administrering tid	Sköljdropp NaCl, ml	Spoldropp NaCl, ml	Kemiskt stabil	Kommentar
500							
Etoposid	1000 NaCl	iv inf	1 tim			72 tim, kallt	Konc ≤ 0,4 mg/ml
Daktinomycin	250 NaCl	iv inf	30 min			72 tim, kallt	
Metotrexat	250 NaCl	iv inf	30 min			72 tim, kallt	
Metotrexat	500 NaCl	iv inf	12 tim				
250							
Vinkristin	250 NaCl	iv inf	30 min			72 tim, kallt	
Cyklofosfamid	250 NaCl	iv inf	30 min			72 tim, kallt	

XXVII. CE high dose chemotherapy with autologous stemcell support

Day T -7	Admission. Recent evaluation of uncorrected GFR using Cr-EDTA/iohexol must have been performed! Renal function considerations ¹ . If body surface exceeds 2.2m ² individual evaluation of patient constitution must be done. Start Allopurinol 300 mg x 1 Blood samples including AFP and β-hCG
Day T -6	Antiemetic prophylaxis Etoposide 560mg/m ² in 4000ml 0.9% NaCl over 6 hours (maximum concentration 0.4 mg/ml), maximum dose 1340mg² Carboplatin 8 x (GFR + 25) mg in 1000 ml 5% glucose over 1-hour, maximum dose 1085mg³ GFR should be the uncorrected/absolute value
Day T -5	Antiemetic prophylaxis Etoposide 560mg/m ² in 4000ml 0.9% NaCl over 6 hours (maximum concentration 0.4 mg/ml), maximum dose 1340mg² Carboplatin 8 x (GFR + 25) mg in 1000 ml 5% glucose over 1-hour, maximum dose 1085mg³ GFR should be the uncorrected/absolute value
Day T -4	Antiemetic prophylaxis Etoposide 560mg/m ² in 4000ml 0.9% NaCl over 6 hours (maximum concentration 0.4 mg/ml), maximum dose 1340mg² Carboplatin 8 x (GFR + 25) mg in 1000 ml 5% glucose over 1-hour, maximum dose 1085mg³ GFR should be the uncorrected/absolute value
Day T -3	Antiemetic prophylaxis Etoposide 560mg/m ² in 4000ml 0.9% NaCl over 6 hours (maximum concentration 0.4 mg/ml), maximum dose 1340mg² Carboplatin 8 x (GFR + 25) mg in 1000 ml 5% glucose over 1-hour, maximum dose 1085mg³ GFR should be the uncorrected/absolute value
Day T -2	
Day T -1	Cessation of allopurinol
Day T 0	Autologous stem cell infusion , approximately 72 hours after end of chemotherapy
Day T +1	Start G-CSF 5µg/kg until neutrophils are >1.0 for three consecutive days

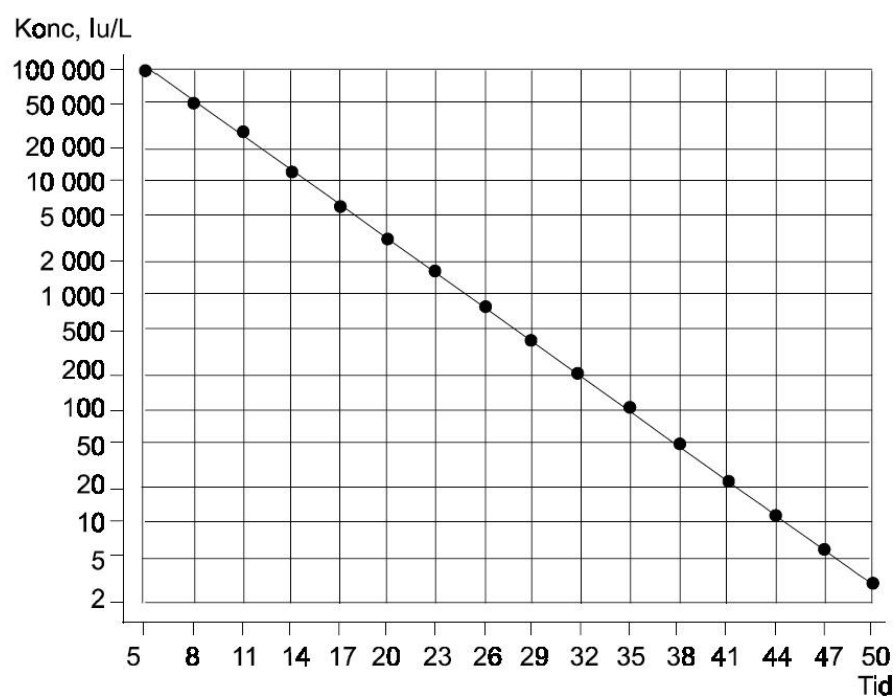
¹If uncorrected/absolute GFR >120mL/min, or the patients has nonconforming body composition e.g. obesity or edema the following calculation tool can be used www.egfr.se. If diverging results between methods extra vigilance regarding the dosing of carboplatin is indicated.²The maximum dose of etoposide calculated from a body surface of 2.4m².³The maximum dose of carboplatin calculated from an uncorrected/absolute GFR of 130mL/min.

Additional notes: The patient should be monitored closely in regard to fluid balance. The patient should receive a minimum of 6 l fluid/m²/24 hours. If patients have fluid retention diuretics should be given. Carboplatin can also be prepared in 0.9% NaCl. In case of infection during or after HDCT aminoglycosides are contraindicated.

XXVIII. β -hCG Half Life Chart

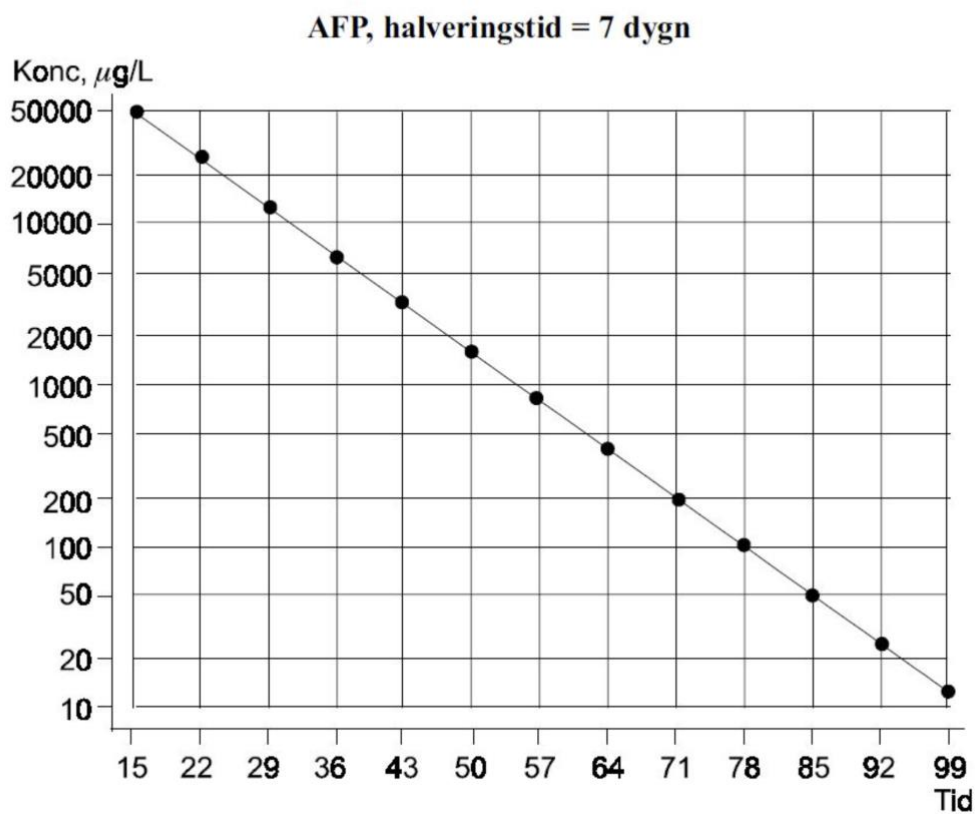
HCG, plot – halveringstid

β -HCG, halveringstid = 3 dygn



XXIX. AFP Half Life Chart

AFP, plot – halveringstid



References

1. Norway CRO. Cancer in Norway 2018 - Cancer incidence, mortality, survival and prevalence in Norway. 2019.
2. Socialstyrelsen. Cancer Incidence in Sweden 2018. 2019.
3. Ehrlich Y, Beck SD, Foster RS, Bihrl R, Einhorn LH. Serum tumor markers in testicular cancer. *Urol Oncol*. 2013;31(1):17-23.
4. Christensen TB, Engbaek F, Marqversen J, Nielsen SI, Kamby C, von der Maase H. 125I-labelled human chorionic gonadotrophin (hCG) as an elimination marker in the evaluation of hCG decline during chemotherapy in patients with testicular cancer. *Br J Cancer*. 1999;80(10):1577-81.
5. Kliesch S, Thomaidis T, Schutte B, Puhse G, Kater B, Roth S, et al. Update on the diagnostic safety for detection of testicular intraepithelial neoplasia (TIN). *APMIS*. 2003;111(1):70-4; discussion 5.
6. Weissbach L, Bussar-Maatz R, Mann K. The value of tumor markers in testicular seminomas. Results of a prospective multicenter study. *Eur Urol*. 1997;32(1):16-22.
7. Almstrup K, Lobo J, Morup N, Belge G, Rajpert-De Meyts E, Looijenga LHJ, et al. Application of miRNAs in the diagnosis and monitoring of testicular germ cell tumours. *Nat Rev Urol*. 2020;17(4):201-13.
8. Eberhard J, Stahl O, Giwercman Y, Cwikiel M, Cavallin-Stahl E, Lundin KB, et al. Impact of therapy and androgen receptor polymorphism on sperm concentration in men treated for testicular germ cell cancer: a longitudinal study. *Hum Reprod*. 2004;19(6):1418-25.
9. Weibring K, Nord C, Stahl O, Eberhard J, Sandberg K, Johansson H, et al. Sperm count in Swedish clinical stage I testicular cancer patients following adjuvant treatment. *Ann Oncol*. 2019;30(4):604-11.
10. Skoogh J, Steineck G, Cavallin-Stahl E, Wilderang U, Hakansson UK, Johansson B, et al. Feelings of loss and uneasiness or shame after removal of a testicle by orchidectomy: a population-based long-term follow-up of testicular cancer survivors. *International Journal of Andrology*. 2011;34(2):183-92.
11. Dieckmann KP, Anheuser P, Schmidt S, Soyka-Hundt B, Pichlmeier U, Schriefer P, et al. Testicular prostheses in patients with testicular cancer - acceptance rate and patient satisfaction. *BMC Urol*. 2015;15:16.
12. Capelouto CC, Clark PE, Ransil BJ, Loughlin KR. A review of scrotal violation in testicular cancer: is adjuvant local therapy necessary? *J Urol*. 1995;153(3 Pt 2):981-5.
13. Leibovitch I, Baniel J, Foster RS, Donohue JP. The clinical implications of procedural deviations during orchiectomy for nonseminomatous testis cancer. *J Urol*. 1995;154(3):935-9.
14. Khetpal R, Katz MD, Cox M, Arnaoutakis K. The role of salvage hemiscrotoectomy in testicular cancer after scrotal contamination: a case report and literature review. *Clinical genitourinary cancer*. 2014;12(3):e103-5.
15. Harland SJ, Cook PA, Fossa SD, Horwich A, Mead GM, Parkinson MC, et al. Intratubular germ cell neoplasia of the contralateral testis in testicular cancer: defining a high risk group. *J Urol*. 1998;160(4):1353-7.
16. Coogan CL, Foster RS, Simmons GR, Tognoni PG, Roth BJ, Donohue JP. Bilateral testicular tumors: management and outcome in 21 patients. *Cancer*. 1998;83(3):547-52.
17. Albers P, Goll A, Bierhoff E, Schoeneich G, Muller SC. Clinical course and histopathologic risk factor assessment in patients with bilateral testicular germ cell tumors. *Urology*. 1999;54(4):714-8.
18. Dieckmann KP, Kulejewski M, Pichlmeier U, Loy V. Diagnosis of contralateral testicular intraepithelial neoplasia (TIN) in patients with testicular germ cell cancer: systematic two-site biopsies are more sensitive than a single random biopsy. *Eur Urol*. 2007;51(1):175-83; discussion 83-5.
19. Dieckmann KP, Heinemann V, Frey U, Pichlmeier U, German Testicular Cancer Study G. How harmful is contralateral testicular biopsy?--an analysis of serial imaging studies and a prospective evaluation of surgical complications. *Eur Urol*. 2005;48(4):662-72.
20. Balawender K, Orkisz S, Wisz P. Testicular microlithiasis: what urologists should know. A review of the current literature. *Cent European J Urol*. 2018;71(3):310-4.
21. Bang AK, Petersen JH, Petersen PM, Andersson AM, Daugaard G, Jorgensen N. Testosterone production is better preserved after 16 than 20 Gray irradiation treatment against testicular carcinoma in situ cells. *Int J Radiat Oncol Biol Phys*. 2009;75(3):672-6.
22. Kleinschmidt K, Dieckmann KP, Georgiew A, Loy V, Weissbach L. Chemotherapy is of limited efficacy in the control of contralateral testicular intraepithelial neoplasia in patients with testicular germ cell cancer. *Oncology*. 2009;77(1):33-9.
23. MacMahon H, Naidich DP, Goo JM, Lee KS, Leung ANC, Mayo JR, et al. Guidelines for Management of Incidental Pulmonary Nodules Detected on CT Images: From the Fleischner Society 2017. *Radiology*. 2017;284(1):228-43.
24. Forsberg L, Dale L, Hoiem L, Magnusson A, Mikulowski P, Olsson AM, et al. Computed tomography in early stages of testicular carcinoma. Size of normal retroperitoneal lymph nodes and lymph nodes in patients with metastases in stage II A. A SWENOTECA study: Swedish-Norwegian Testicular Cancer Project. *Acta Radiol Diagn (Stockh)*. 1986;27(5):569-74.
25. Hale GR, Teplitsky S, Truong H, Gold SA, Bloom JB, Agarwal PK. Lymph node imaging in testicular cancer. *Transl Androl Urol*. 2018;7(5):864-74.
26. Handbook for reporting results of cancer treatment. Geneva, Switzerland 1979.

27. Honecker F, Aparicio J, Berney D, Beyer J, Bokemeyer C, Cathomas R, et al. ESMO Consensus Conference on testicular germ cell cancer: diagnosis, treatment and follow-up. *Ann Oncol.* 2018;29(8):1658-86.
28. Sohaib SA, Koh DM, Barbachano Y, Parikh J, Husband JE, Dearnaley DP, et al. Prospective assessment of MRI for imaging retroperitoneal metastases from testicular germ cell tumours. *Clin Radiol.* 2009;64(4):362-7.
29. Huddart RA, O'Doherty MJ, Padhani A, Rustin GJ, Mead GM, Joffe JK, et al. 18fluorodeoxyglucose positron emission tomography in the prediction of relapse in patients with high-risk, clinical stage I nonseminomatous germ cell tumors: preliminary report of MRC Trial TE22--the NCRI Testis Tumour Clinical Study Group. *J Clin Oncol.* 2007;25(21):3090-5.
30. de Wit M, Brenner W, Hartmann M, Kotzerke J, Hellwig D, Lehmann J, et al. [18F]-FDG-PET in clinical stage I/II non-seminomatous germ cell tumours: results of the German multicentre trial. *Ann Oncol.* 2008;19(9):1619-23.
31. Albers P, Bender H, Yilmaz H, Schoeneich G, Biersack HJ, Mueller SC. Positron emission tomography in the clinical staging of patients with Stage I and II testicular germ cell tumors. *Urology.* 1999;53(4):808-11.
32. Spermon JR, De Geus-Oei LF, Kiemeny LA, Witjes JA, Oyen WJ. The role of (18)fluoro-2-deoxyglucose positron emission tomography in initial staging and re-staging after chemotherapy for testicular germ cell tumours. *BJU Int.* 2002;89(6):549-56.
33. Beyer J, Albers P, Altena R, Aparicio J, Bokemeyer C, Busch J, et al. Maintaining success, reducing treatment burden, focusing on survivorship: highlights from the third European consensus conference on diagnosis and treatment of germ-cell cancer. *Ann Oncol.* 2013;24(4):878-88.
34. Tandstad T, Smaaland R, Solberg A, Bremnes RM, Langberg CW, Laurell A, et al. Management of seminomatous testicular cancer: a binational prospective population-based study from the Swedish norwegian testicular cancer study group. *J Clin Oncol.* 2011;29(6):719-25.
35. Warde P, Specht L, Horwich A, Oliver T, Panzarella T, Gospodarowicz M, et al. Prognostic factors for relapse in stage I seminoma managed by surveillance: a pooled analysis. *J Clin Oncol.* 2002;20(22):4448-52.
36. Daugaard G, Petersen PM, Rorth M. Surveillance in stage I testicular cancer. *APMIS.* 2003;111(1):76-83; discussion -5.
37. Kollmannsberger C, Tyldesley S, Moore C, Chi KN, Murray N, Daneshmand S, et al. Evolution in management of testicular seminoma: population-based outcomes with selective utilization of active therapies. *Ann Oncol.* 2010.
38. Chung PW, Daugaard G, Tyldesley S, Panzarella T, Kollmannsberger CK, Gospodarowicz M, et al. Prognostic factors for relapse in stage I seminoma managed with surveillance: A validation study. *J Clin Oncol.* 2010;28(7s):suppl; abstr 4535.
39. Aparicio J, Maroto P, del Muro XG, Guma J, Sanchez-Munoz A, Margeli M, et al. Risk-adapted treatment in clinical stage I testicular seminoma: the third Spanish Germ Cell Cancer Group study. *J Clin Oncol.* 2011;29(35):4677-81.
40. Tandstad T, Stahl O, Dahl O, Haugnes HS, Hakansson U, Karlsdottir A, et al. Treatment of stage I seminoma, with one course of adjuvant carboplatin or surveillance, risk-adapted recommendations implementing patient autonomy, a report from the Swedish and Norwegian Testicular Cancer Group (SWENOTECA). *Ann Oncol.* 2016.
41. Oliver RT, Mason MD, Mead GM, von der Maase H, Rustin GJ, Joffe JK, et al. Radiotherapy versus single-dose carboplatin in adjuvant treatment of stage I seminoma: a randomised trial. *Lancet.* 2005;366(9482):293-300.
42. Oliver RT, Mead GM, Rustin GJ, Joffe JK, Aass N, Coleman R, et al. Randomized Trial of Carboplatin Versus Radiotherapy for Stage I Seminoma: Mature Results on Relapse and Contralateral Testis Cancer Rates in MRC TE19/EORTC 30982 Study (ISRCTN27163214). *J Clin Oncol.* 2011;29(8):957-62.
43. Tandstad T, Cavallin-Stahl E, Dahl O, Haugnes HS, Langberg C, Laurell A, et al. Management of clinical stage I seminomatous testicular cancer: A report from SWENOTECA. *J Clin Oncol.* 2014;32(5s):suppl; abstract 4508.
44. Aparicio J, Germa JR, Garcia del Muro X, Maroto P, Arranz JA, Saenz A, et al. Risk-adapted management for patients with clinical stage I seminoma: the Second Spanish Germ Cell Cancer Cooperative Group study. *J Clin Oncol.* 2005;23(34):8717-23.
45. Steiner H, Holtl L, Wirtenberger W, Berger AP, Bartsch G, Hobisch A. Long-term experience with carboplatin monotherapy for clinical stage I seminoma: a retrospective single-center study. *Urology.* 2002;60(2):324-8.
46. Steiner H, Scheiber K, Berger AP, Rein P, Hobisch A, Aufderklamm J, et al. Retrospective multicentre study of carboplatin monotherapy for clinical stage I seminoma. *BJU Int.* 2011;107(7):1074-9.
47. Pont J, Albrecht W, Postner G, Sellner F, Angel K, Holtl W. Adjuvant chemotherapy for high-risk clinical stage I nonseminomatous testicular germ cell cancer: long-term results of a prospective trial. *J Clin Oncol.* 1996;14(2):441-8.
48. Klepp O, Olsson AM, Ous S, Nilsson S, Hoisaether PA, Tveter K. Early clinical stages of nonseminomatous testis cancer. Evaluation of the primary treatment and follow-up procedures of the SWENOTECA project. *Scand J Urol Nephrol.* 1991;25(3):179-90.
49. Kollmannsberger C, Moore C, Chi KN, Murray N, Daneshmand S, Gleave M, et al. Non-risk-adapted surveillance for patients with stage I nonseminomatous testicular germ-cell tumors: diminishing treatment-related morbidity while maintaining efficacy. *Ann Oncol.* 2010;21(6):1296-301.
50. Sturgeon JF, Moore MJ, Kakiashvili DM, Duran I, Anson-Cartwright LC, Berthold DR, et al. Non-Risk-Adapted Surveillance in Clinical Stage I Nonseminomatous Germ Cell Tumors: The Princess Margaret Hospital's Experience. *Eur Urol.* 2010.
51. Kollmannsberger C, Tandstad T, Bedard PL, Cohn-Cedermark G, Chung PW, Jewett MA, et al. Patterns of relapse in patients with clinical stage I testicular cancer managed with active surveillance. *J Clin Oncol.* 2015;33(1):51-7.

52. Tandstad T, Stahl O, Hakansson U, Dahl O, Haugnes HS, Klepp OH, et al. One course of adjuvant BEP in clinical stage I nonseminoma mature and expanded results from the SWENOTECA group. *Ann Oncol.* 2014;25(11):2167-72.
53. Tandstad T, Dahl O, Cohn-Cedermark G, Cavallin-Stahl E, Stierner U, Solberg A, et al. Risk-adapted treatment in clinical stage I nonseminomatous germ cell testicular cancer: the SWENOTECA management program. *J Clin Oncol.* 2009;27(13):2122-8.
54. Nichols CR, Roth B, Albers P, Einhorn LH, Foster R, Daneshmand S, et al. Active surveillance is the preferred approach to clinical stage I testicular cancer. *J Clin Oncol.* 2013;31(28):3490-3.
55. Giannatempo P, Pond GR, Sonpavde G, Albany C, Lorient Y, Sweeney CJ, et al. Treatment and Clinical Outcomes of Patients with Teratoma with Somatic-Type Malignant Transformation: An International Collaboration. *J Urol.* 2016;196(1):95-100.
56. International Germ Cell Consensus Classification: a prognostic factor-based staging system for metastatic germ cell cancers. International Germ Cell Cancer Collaborative Group. *J Clin Oncol.* 1997;15(2):594-603.
57. Classen J, Schmidberger H, Meisner C, Souchon R, Sautter-Bihl ML, Sauer R, et al. Radiotherapy for stages IIA/B testicular seminoma: final report of a prospective multicenter clinical trial. *J Clin Oncol.* 2003;21(6):1101-6.
58. Hellesnes R, Kvammen O, Myklebust TA, Bremnes RM, Karlsdottir A, Negaard HFS, et al. Continuing increased risk of second cancer in long-term testicular cancer survivors after treatment in the cisplatin era. *Int J Cancer.* 2019.
59. Alexander EJ, White IM, Horwich A. Update on management of seminoma. *Indian journal of urology : IJU : journal of the Urological Society of India.* 2010;26(1):82-91.
60. Zagars GK, Ballo MT, Lee AK, Strom SS. Mortality after cure of testicular seminoma. *J Clin Oncol.* 2004;22(4):640-7.
61. Horwich A, Fossa SD, Stenning S, Bliss J, Hall EJ. Risk of second cancers among a cohort of 2,703 long-term survivors of testicular seminoma treated with radiotherapy. *J Clin Oncol.* 2010;28(7s):suppl; abstr 4538.
62. Hu B, Daneshmand S. Retroperitoneal Lymph Node Dissection as Primary Treatment for Metastatic Seminoma. *Adv Urol.* 2018;2018:7978958.
63. Heidenreich A, Paffenholz P, Nestler T, Pfister D, Daneshmand S. Role of primary retroperitoneal lymph node dissection in stage I and low-volume metastatic germ cell tumors. *Curr Opin Urol.* 2020;30(2):251-7.
64. Heidenreich A, Albers P, Hartmann M, Kliesch S, Kohrmann KU, Krege S, et al. Complications of primary nerve sparing retroperitoneal lymph node dissection for clinical stage I nonseminomatous germ cell tumors of the testis: experience of the German Testicular Cancer Study Group. *J Urol.* 2003;169(5):1710-4.
65. Beck SD, Peterson MD, Bihle R, Donohue JP, Foster RS. Short-term morbidity of primary retroperitoneal lymph node dissection in a contemporary group of patients. *J Urol.* 2007;178(2):504-6; discussion 6.
66. Baniel J, Foster RS, Rowland RG, Bihle R, Donohue JP. Complications of primary retroperitoneal lymph node dissection. *J Urol.* 1994;152(2 Pt 1):424-7.
67. Mezvrishvili Z, Managadze L. Retroperitoneal lymph node dissection for high-risk stage I and stage IIA seminoma. *Int Urol Nephrol.* 2006;38(3-4):615-9.
68. Hu B, Shah S, Shojaei S, Daneshmand S. Retroperitoneal Lymph Node Dissection as First-Line Treatment of Node-Positive Seminoma. *Clinical genitourinary cancer.* 2015;13(4):e265-e9.
69. Chung PW, Gospodarowicz MK, Panzarella T, Jewett MA, Sturgeon JF, Tew-George B, et al. Stage II testicular seminoma: patterns of recurrence and outcome of treatment. *Eur Urol.* 2004;45(6):754-59; discussion 9-60.
70. Domont J, Massard C, Patrikidou A, Bossi A, de Crevoisier R, Rose M, et al. A risk-adapted strategy of radiotherapy or cisplatin-based chemotherapy in stage II seminoma. *Urol Oncol.* 2013;31(5):697-705.
71. Albers P, Albrecht W, Algaba F, Bokemeyer C, Cohn-Cedermark G, Fizazi K, et al. EAU Guidelines on Testicular Cancer: 2011 Update. *European Urology.* 2011;60(2):304-19.
72. Beyer J, Albers P, Altena R, Aparicio J, Bokemeyer C, Busch J, et al. Maintaining success, reducing treatment burden, focusing on survivorship: highlights from the third European consensus conference on diagnosis and treatment of germ-cell cancer. *Annals of Oncology.* 2012.
73. de Wit R, Roberts JT, Wilkinson PM, de Mulder PH, Mead GM, Fossa SD, et al. Equivalence of three or four cycles of bleomycin, etoposide, and cisplatin chemotherapy and of a 3- or 5-day schedule in good-prognosis germ cell cancer: a randomized study of the European Organization for Research and Treatment of Cancer Genitourinary Tract Cancer Cooperative Group and the Medical Research Council. *J Clin Oncol.* 2001;19(6):1629-40.
74. Horwich A, Oliver RT, Wilkinson PM, Mead GM, Harland SJ, Cullen MH, et al. A medical research council randomized trial of single agent carboplatin versus etoposide and cisplatin for advanced metastatic seminoma. MRC Testicular Tumour Working Party. *Br J Cancer.* 2000;83(12):1623-9.
75. Bokemeyer C, Kollmannsberger C, Stenning S, Hartmann JT, Horwich A, Clemm C, et al. Metastatic seminoma treated with either single agent carboplatin or cisplatin-based combination chemotherapy: a pooled analysis of two randomised trials. *Br J Cancer.* 2004;91(4):683-7.
76. Tookman L, Rashid S, Matakidou A, Phillips M, Wilson P, Ansell W, et al. Carboplatin AUC 10 for IGCCCG good prognosis metastatic seminoma. *Acta Oncol.* 2013;52(5):987-93.
77. Puc HS, Heelan R, Mazumdar M, Herr H, Scheinfeld J, Vlamis V, et al. Management of residual mass in advanced seminoma: results and recommendations from the Memorial Sloan-Kettering Cancer Center. *J Clin Oncol.* 1996;14(2):454-60.

78. Flechon A, Bompas E, Biron P, Droz JP. Management of post-chemotherapy residual masses in advanced seminoma. *J Urol*. 2002;168(5):1975-9.
79. Ravi R, Ong J, Oliver RT, Badenoch DF, Fowler CG, Hendry WF. The management of residual masses after chemotherapy in metastatic seminoma. *BJU Int*. 1999;83(6):649-53.
80. Bachner M, Lorient Y, Gross-Goupil M, Zucali PA, Horwich A, Germa-Lluch JR, et al. 2-18fluoro-deoxy-D-glucose positron emission tomography (FDG-PET) for postchemotherapy seminoma residual lesions: a retrospective validation of the SEMPET trial. *Ann Oncol*. 2011.
81. De Santis M, Becherer A, Bokemeyer C, Stoiber F, Oechsle K, Sellner F, et al. 2-18fluoro-deoxy-D-glucose positron emission tomography is a reliable predictor for viable tumor in postchemotherapy seminoma: an update of the prospective multicentric SEMPET trial. *J Clin Oncol*. 2004;22(6):1034-9.
82. Cathomas R, Klingbiel D, Bernard B, Lorch A, Garcia Del Muro X, Morelli F, et al. Questioning the Value of Fluorodeoxyglucose Positron Emission Tomography for Residual Lesions After Chemotherapy for Metastatic Seminoma: Results of an International Global Germ Cell Cancer Group Registry. *J Clin Oncol*. 2018;JCO1800210.
83. Hartmann JT, Candelaria M, Kuczyk MA, Schmoll HJ, Bokemeyer C. Comparison of histological results from the resection of residual masses at different sites after chemotherapy for metastatic non-seminomatous germ cell tumours. *Eur J Cancer*. 1997;33(6):843-7.
84. Masterson TA, Shayegan B, Carver BS, Bajorin DF, Feldman DR, Motzer RJ, et al. Clinical impact of residual extraretroperitoneal masses in patients with advanced nonseminomatous germ cell testicular cancer. *Urology*. 2012;79(1):156-9.
85. Besse B, Grunenwald D, Flechon A, Caty A, Chevreau C, Culine S, et al. Nonseminomatous germ cell tumors: assessing the need for postchemotherapy contralateral pulmonary resection in patients with ipsilateral complete necrosis. *J Thorac Cardiovasc Surg*. 2009;137(2):448-52.
86. Schirren J, Trainer S, Eberlein M, Lorch A, Beyer J, Bolukbas S. The role of residual tumor resection in the management of nonseminomatous germ cell cancer of testicular origin. *Thorac Cardiovasc Surg*. 2012;60(6):405-12.
87. Motzer RJ, Nichols CJ, Margolin KA, Bacik J, Richardson PG, Vogelzang NJ, et al. Phase III randomized trial of conventional-dose chemotherapy with or without high-dose chemotherapy and autologous hematopoietic stem-cell rescue as first-line treatment for patients with poor-prognosis metastatic germ cell tumors. *J Clin Oncol*. 2007;25(3):247-56.
88. Fizazi K, Pagliaro L, Laplanche A, Flechon A, Mardiat J, Geoffrois L, et al. Personalised chemotherapy based on tumour marker decline in poor prognosis germ-cell tumours (GETUG 13): a phase 3, multicentre, randomised trial. *Lancet Oncol*. 2014;15(13):1442-50.
89. Olofsson SE, Tandstad T, Jerkeman M, Dahl O, Stahl O, Klepp O, et al. Population-based study of treatment guided by tumor marker decline in patients with metastatic nonseminomatous germ cell tumor: a report from the Swedish-Norwegian Testicular Cancer Group. *J Clin Oncol*. 2011;29(15):2032-9.
90. van Dijk MR, Steyerberg EW, Habbema JD. Survival of non-seminomatous germ cell cancer patients according to the IGCC classification: An update based on meta-analysis. *Eur J Cancer*. 2006;42(7):820-6.
91. Foster RS, Baniel J, Leibovitch I, Curran M, Bihle R, Rowland R, et al. Teratoma in the orchiectomy specimen and volume of metastasis are predictors of retroperitoneal teratoma in low stage nonseminomatous testis cancer. *J Urol*. 1996;155(6):1943-5.
92. Stephenson AJ, Bosl GJ, Motzer RJ, Bajorin DF, Stasi JP, Sheinfeld J. Nonrandomized comparison of primary chemotherapy and retroperitoneal lymph node dissection for clinical stage IIA and IIB nonseminomatous germ cell testicular cancer. *J Clin Oncol*. 2007;25(35):5597-602.
93. de Wit R, Skoneczna I, Daugaard G, De Santis M, Garin A, Aass N, et al. Randomized phase III study comparing paclitaxel-bleomycin, etoposide, and cisplatin (BEP) to standard BEP in intermediate-prognosis germ-cell cancer: intergroup study EORTC 30983. *J Clin Oncol*. 2012;30(8):792-9.
94. Adra N, Althouse SK, Liu H, Brames MJ, Hanna NH, Einhorn LH, et al. Prognostic factors in patients with poor-risk germ-cell tumors: a retrospective analysis of the Indiana University experience from 1990 to 2014. *Ann Oncol*. 2016;27(5):875-9.
95. Oing C, Oechsle K, Necchi A, Lorient Y, De Giorgi U, Flechon A, et al. Impact of primary metastatic bone disease in germ cell tumors: results of an International Global Germ Cell Tumor Collaborative Group G3 Registry Study. *Ann Oncol*. 2017;28(3):576-82.
96. Adra N, Albany C, Sonneburg D, Tong Y, Hanna N, Einhorn L. A retrospective analysis of patients with poor-risk germ cell tumor (PRGCT) treated at Indiana University from 2000 to 2010. *J Clin Oncol*. 2014;31:(suppl; abstr 4557).
97. Feldman DR, Lorch A, Kramar A, Albany C, Einhorn LH, Giannatempo P, et al. Brain Metastases in Patients With Germ Cell Tumors: Prognostic Factors and Treatment Options--An Analysis From the Global Germ Cell Cancer Group. *J Clin Oncol*. 2016;34(4):345-51.
98. Kollmannsberger C, Nichols C, Meisner C, Mayer F, Kanz L, Bokemeyer C. Identification of prognostic subgroups among patients with metastatic 'IGCCCG poor-prognosis' germ-cell cancer: an explorative analysis using cart modeling. *Ann Oncol*. 2000;11(9):1115-20.
99. Fizazi K, Prow DM, Do KA, Wang X, Finn L, Kim J, et al. Alternating dose-dense chemotherapy in patients with high volume disseminated non-seminomatous germ cell tumours. *Br J Cancer*. 2002;86(10):1555-60.
100. Christian JA, Huddart RA, Norman A, Mason M, Fossa S, Aass N, et al. Intensive induction chemotherapy with CBOP/BEP in patients with poor prognosis germ cell tumors. *J Clin Oncol*. 2003;21(5):871-7.

101. Huddart RA, Gabe R, Cafferty FH, Pollock P, White JD, Shamash J, et al. A randomised phase 2 trial of intensive induction chemotherapy (CBOP/BEP) and standard BEP in poor-prognosis germ cell tumours (MRC TE23, CRUK 05/014, ISRCTN 53643604). *Eur Urol*. 2015;67(3):534-43.
102. Germa-Lluch JR, Garcia del Muro X, Tabernero JM, Sanchez M, Aparicio J, Alba E, et al. BOMP/EPI intensive alternating chemotherapy for IGCCC poor-prognosis germ-cell tumors: the Spanish Germ-Cell Cancer Group experience (GG). *Ann Oncol*. 1999;10(3):289-93.
103. Schmoll HJ, Kollmannsberger C, Metzner B, Hartmann JT, Schleucher N, Schoffski P, et al. Long-term results of first-line sequential high-dose etoposide, ifosfamide, and cisplatin chemotherapy plus autologous stem cell support for patients with advanced metastatic germ cell cancer: an extended phase I/II study of the German Testicular Cancer Study Group. *J Clin Oncol*. 2003;21(22):4083-91.
104. Bhalu N, Coleman JM, Radstone CR, Horsman JM, George J, Hancock BW, et al. The management and survival of patients with advanced germ-cell tumours: improving outcome in intermediate and poor prognosis patients. *Clin Oncol (R Coll Radiol)*. 2004;16(1):40-7.
105. Fossa SD, Paluchowska B, Horwich A, Kaiser G, de Mulder PH, Koriakine O, et al. Intensive induction chemotherapy with C-BOP/BEP for intermediate- and poor-risk metastatic germ cell tumours (EORTC trial 30948). *Br J Cancer*. 2005;93(11):1209-14.
106. Hartmann JT, Gauler T, Metzner B, Gerl A, Casper J, Rick O, et al. Phase I/II study of sequential dose-intensified ifosfamide, cisplatin, and etoposide plus paclitaxel as induction chemotherapy for poor prognosis germ cell tumors by the German Testicular Cancer Study Group. *J Clin Oncol*. 2007;25(36):5742-7.
107. Tryakin A, Fedyanin M, Kanagavel D, Fainstein I, Sergeev J, Polockij B, et al. Paclitaxel+BEP (T-BEP) regimen as induction chemotherapy in poor prognosis patients with nonseminomatous germ cell tumors: a phase II study. *Urology*. 2011;78(3):620-5.
108. Hinton S, Catalano PJ, Einhorn LH, Nichols CR, David Crawford E, Vogelzang N, et al. Cisplatin, etoposide and either bleomycin or ifosfamide in the treatment of disseminated germ cell tumors: final analysis of an intergroup trial. *Cancer*. 2003;97(8):1869-75.
109. Culine S, Kramar A, Theodore C, Geoffrois L, Chevreau C, Biron P, et al. Randomized trial comparing bleomycin/etoposide/cisplatin with alternating cisplatin/cyclophosphamide/doxorubicin and vinblastine/bleomycin regimens of chemotherapy for patients with intermediate- and poor-risk metastatic nonseminomatous germ cell tumors: Genito-Urinary Group of the French Federation of Cancer Centers Trial T93MP. *J Clin Oncol*. 2008;26(3):421-7.
110. Daugaard G, Skoneczna I, Aass N, De Wit R, De Santis M, Dumez H, et al. A randomized phase III study comparing standard dose BEP with sequential high-dose cisplatin, etoposide, and ifosfamide (VIP) plus stem-cell support in males with poor-prognosis germ-cell cancer. An intergroup study of EORTC, GTCSCG, and Grupo Germinal (EORTC 30974). *Ann Oncol*. 2010.
111. Fizazi K, Delva R, Caty A, Chevreau C, Kerbrat P, Rolland F, et al. A risk-adapted study of cisplatin and etoposide, with or without ifosfamide, in patients with metastatic seminoma: results of the GETUG S99 multicenter prospective study. *Eur Urol*. 2014;65(2):381-6.
112. Fizazi K, Oldenburg J, Dunant A, Chen I, Salvioni R, Hartmann JT, et al. Assessing prognosis and optimizing treatment in patients with postchemotherapy viable nonseminomatous germ-cell tumors (NSGCT): results of the sCR2 international study. *Annals of Oncology*. 2008;19(2):259-64.
113. Nonomura N, Nagahara A, Oka D, Mukai M, Nakai Y, Nakayama M, et al. Brain metastases from testicular germ cell tumors: a retrospective analysis. *Int J Urol*. 2009;16(11):887-93.
114. Oechsle K, Bokemeyer C. Treatment of brain metastases from germ cell tumors. *Hematol Oncol Clin North Am*. 2011;25(3):605-13, ix.
115. Patel HD, Singla N, Ghandour RA, Freifeld Y, Cheaib JG, Woldu SL, et al. Site of extranodal metastasis impacts survival in patients with testicular germ cell tumors. *Cancer*. 2019;125(22):3947-52.
116. Fossa SD, Bokemeyer C, Gerl A, Culine S, Jones WG, Mead GM, et al. Treatment outcome of patients with brain metastases from malignant germ cell tumors. *Cancer*. 1999;85(4):988-97.
117. Jacus MO, Daryani VM, Harstead KE, Patel YT, Throm SL, Stewart CF. Pharmacokinetic Properties of Anticancer Agents for the Treatment of Central Nervous System Tumors: Update of the Literature. *Clin Pharmacokinet*. 2016;55(3):297-311.
118. Sawrie SM, Guthrie BL, Spencer SA, Nordal RA, Meredith RF, Markert JM, et al. Predictors of distant brain recurrence for patients with newly diagnosed brain metastases treated with stereotactic radiosurgery alone. *Int J Radiat Oncol Biol Phys*. 2008;70(1):181-6.
119. Doyle DM, Einhorn LH. Delayed effects of whole brain radiotherapy in germ cell tumor patients with central nervous system metastases. *Int J Radiat Oncol Biol Phys*. 2008;70(5):1361-4.
120. Brown PD, Pugh S, Laack NN, Wefel JS, Khuntia D, Meyers C, et al. Memantine for the prevention of cognitive dysfunction in patients receiving whole-brain radiotherapy: a randomized, double-blind, placebo-controlled trial. *Neuro Oncol*. 2013;15(10):1429-37.
121. Oing C, Oechsle K, Necchi A, Loriot Y, De Giorgi U, Flechon A, et al. Bone metastases in germ cell tumors: Results from an international data base. *J Clin Oncol*. 2014(32):Supple; abstr 4559.
122. Nini A, Konieczny M, Winter C, Lusch A, Krauspe R, Albers P. Surgical management and outcomes of patients with bone metastases in germ cell tumors: A case series. *Urol Oncol*. 2018;36(2):82 e1- e5.

123. Gennaro N, Sconfienza LM, Ambrogi F, Boveri S, Lanza E. Thermal ablation to relieve pain from metastatic bone disease: a systematic review. *Skeletal Radiol.* 2019;48(8):1161-9.
124. Griggs JJ, Mangu PB, Anderson H, Balaban EP, Dignam JJ, Hryniuk WM, et al. Appropriate chemotherapy dosing for obese adult patients with cancer: American Society of Clinical Oncology clinical practice guideline. *J Clin Oncol.* 2012;30(13):1553-61.
125. Leu L, Baribeault D. A comparison of the rates of cisplatin (cDDP)--induced nephrotoxicity associated with sodium loading or sodium loading with forced diuresis as a preventative measure. *Journal of oncology pharmacy practice : official publication of the International Society of Oncology Pharmacy Practitioners.* 2010;16(3):167-71.
126. Crona DJ, Faso A, Nishijima TF, McGraw KA, Galsky MD, Milowsky MI. A Systematic Review of Strategies to Prevent Cisplatin-Induced Nephrotoxicity. *Oncologist.* 2017;22(5):609-19.
127. Hartmann JT, Lipp HP. Camptothecin and podophyllotoxin derivatives: inhibitors of topoisomerase I and II - mechanisms of action, pharmacokinetics and toxicity profile. *Drug Saf.* 2006;29(3):209-30.
128. Joel SP, Shah R, Clark PI, Slevin ML. Predicting etoposide toxicity: relationship to organ function and protein binding. *J Clin Oncol.* 1996;14(1):257-67.
129. Haugnes HS, Oldenburg J, Bremnes RM. Pulmonary and cardiovascular toxicity in long-term testicular cancer survivors. *Urol Oncol.* 2015;33(9):399-406.
130. O'Sullivan JM, Huddart RA, Norman AR, Nicholls J, Dearnaley DP, Horwich A. Predicting the risk of bleomycin lung toxicity in patients with germ-cell tumours. *Ann Oncol.* 2003;14(1):91-6.
131. Langberg MK, Berglund-Nord C, Cohn-Cedermark G, Haugnes HS, Tandstad T, Langberg CW. Imatinib may reduce chemotherapy-induced pneumonitis. A report on four cases from the SWENOTECA. *Acta Oncol.* 2018;57(10):1401-6.
132. Sleijfer S. Bleomycin-induced pneumonitis. *Chest.* 2001;120(2):617-24.
133. Donat SM, Levy DA. Bleomycin associated pulmonary toxicity: is perioperative oxygen restriction necessary? *J Urol.* 1998;160(4):1347-52.
134. de Wit R, Sleijfer S, Kaye SB, Horwich A, Mead B, Sleijfer DT, et al. Bleomycin and scuba diving: where is the harm? *Lancet Oncol.* 2007;8(11):954-5.
135. Lorch A, Bascoul-Mollevi C, Kramar A, Einhorn L, Necchi A, Massard C, et al. Conventional-dose versus high-dose chemotherapy as first salvage treatment in male patients with metastatic germ cell tumors: evidence from a large international database. *J Clin Oncol.* 2011;29(16):2178-84.
136. Droz JP, Kramar A, Biron P, Pico JL, Kerbrat P, Peny J, et al. Failure of high-dose cyclophosphamide and etoposide combined with double-dose cisplatin and bone marrow support in patients with high-volume metastatic nonseminomatous germ-cell tumours: mature results of a randomised trial. *Eur Urol.* 2007;51(3):739-46; discussion 47-8.
137. Lorch A, Mollevi A, Kramar A, Einhorn LH, Necchi C. Conventional-dose versus high-dose chemotherapy in relapsed or refractory male germ-cell tumors: A retrospective study in 1,594 patients. *J Clin Oncol.* 2010;28(15s):[suppl: abstr 4513].
138. Pico JL, Rosti G, Kramar A, Wandt H, Koza V, Salvioni R, et al. A randomised trial of high-dose chemotherapy in the salvage treatment of patients failing first-line platinum chemotherapy for advanced germ cell tumours. *Ann Oncol.* 2005;16(7):1152-9.
139. Haugnes HS, Laurell A, Stierner U, Bremnes RM, Dahl O, Cavallin-Stahl E, et al. High-dose chemotherapy with autologous stem cell support in patients with metastatic non-seminomatous testicular cancer - a report from the Swedish Norwegian Testicular Cancer Group (SWENOTECA). *Acta Oncol.* 2012;51(2):168-76.
140. Houck W, Abonour R, Vance G, Einhorn LH. Secondary leukemias in refractory germ cell tumor patients undergoing autologous stem-cell transplantation using high-dose etoposide. *J Clin Oncol.* 2004;22(11):2155-8.
141. Wierecky J, Kollmannsberger C, Boehlke I, Kuczyk M, Schleicher J, Schleucher N, et al. Secondary leukemia after first-line high-dose chemotherapy for patients with advanced germ cell cancer. *J Cancer Res Clin Oncol.* 2005;131(4):255-60.
142. Feldman DR, Sheinfeld J, Bajorin DF, Fischer P, Turkula S, Ishill N, et al. TI-CE high-dose chemotherapy for patients with previously treated germ cell tumors: results and prognostic factor analysis. *J Clin Oncol.* 2010;28(10):1706-13.
143. Lotz JP, Bui B, Gomez F, Theodore C, Caty A, Fizazi K, et al. Sequential high-dose chemotherapy protocol for relapsed poor prognosis germ cell tumors combining two mobilization and cytoreductive treatments followed by three high-dose chemotherapy regimens supported by autologous stem cell transplantation. Results of the phase II multicentric TAXIF trial. *Ann Oncol.* 2005;16(3):411-8.
144. Adra N, Abonour R, Althouse SK, Albany C, Hanna NH, Einhorn LH. High-Dose Chemotherapy and Autologous Peripheral-Blood Stem-Cell Transplantation for Relapsed Metastatic Germ Cell Tumors: The Indiana University Experience. *J Clin Oncol.* 2017;35(10):1096-102.
145. Hamid AA, Markt SC, Vicier C, McDermott K, Richardson P, Ho VT, et al. Autologous Stem-Cell Transplantation Outcomes for Relapsed Metastatic Germ-Cell Tumors in the Modern Era. *Clinical genitourinary cancer.* 2019;17(1):58-64 e1.
146. Martin WG, Ristow KM, Habermann TM, Colgan JP, Witzig TE, Ansell SM. Bleomycin pulmonary toxicity has a negative impact on the outcome of patients with Hodgkin's lymphoma. *J Clin Oncol.* 2005;23(30):7614-20.
147. Iwamoto H, Izumi K, Natsagdorj A, Makino T, Nohara T, Shigehara K, et al. Effectiveness and Safety of Pegfilgrastim in BEP Treatment for Patients with Germ Cell Tumor. *In Vivo.* 2018;32(4):899-903.
148. Fossa SD, Kaye SB, Mead GM, Cullen M, de Wit R, Bodrogi I, et al. Filgrastim during combination chemotherapy of patients with poor-prognosis metastatic germ cell malignancy. *European Organization for Research and*

Treatment of Cancer, Genito-Urinary Group, and the Medical Research Council Testicular Cancer Working Party, Cambridge, United Kingdom. *J Clin Oncol.* 1998;16(2):716-24.

149. Saxman SB, Nichols CR, Einhorn LH. Pulmonary toxicity in patients with advanced-stage germ cell tumors receiving bleomycin with and without granulocyte colony stimulating factor. *Chest.* 1997;111(3):657-60.
150. Weijl NI, Rutten MF, Zwiderman AH, Keizer HJ, Nooy MA, Rosendaal FR, et al. Thromboembolic events during chemotherapy for germ cell cancer: a cohort study and review of the literature. *J Clin Oncol.* 2000;18(10):2169-78.
151. Bezan A, Posch F, Ploner F, Bauernhofer T, Pichler M, Szkandera J, et al. Risk stratification for venous thromboembolism in patients with testicular germ cell tumors. *PLoS One.* 2017;12(4):e0176283.
152. Srikanthan A, Tran B, Beausoleil M, Jewett MA, Hamilton RJ, Sturgeon JF, et al. Large retroperitoneal lymphadenopathy as a predictor of venous thromboembolism in patients with disseminated germ cell tumors treated with chemotherapy. *J Clin Oncol.* 2015;33(6):582-7.
153. Paffenholz P, Grein K, Heidegger I, Nestler T, Grabbert M, Salem J, et al. Predictors of thrombosis in testicular cancer during platinum-based chemotherapy. *World J Urol.* 2019;37(9):1907-16.
154. Gizzi M, Oberic L, Massard C, Poterie A, Le Teuff G, Lorient Y, et al. Predicting and preventing thromboembolic events in patients receiving cisplatin-based chemotherapy for germ cell tumours. *Eur J Cancer.* 2016;69:151-7.
155. Lyman GH, Bohlke K, Falanga A, American Society of Clinical O. Venous thromboembolism prophylaxis and treatment in patients with cancer: American Society of Clinical Oncology clinical practice guideline update. *J Oncol Pract.* 2015;11(3):e442-4.
156. Farge D, Frere C, Connors JM, Ay C, Khorana AA, Munoz A, et al. 2019 international clinical practice guidelines for the treatment and prophylaxis of venous thromboembolism in patients with cancer. *Lancet Oncol.* 2019;20(10):e566-e81.
157. Key NS, Khorana AA, Kuderer NM, Bohlke K, Lee AYY, Arcelus JJ, et al. Venous Thromboembolism Prophylaxis and Treatment in Patients With Cancer: ASCO Clinical Practice Guideline Update. *J Clin Oncol.* 2020;38(5):496-520.
158. Thorsen L, Haugnes HS, Fosså SD, Brydoy M, Tandstad T, Wisløff T, Gjerset GM, Edvardsen E, Larsen K, Sandset PM, Henriksson CA, Raastad T, Negaard H. Thromboembolic events after high-intensity training during cisplatin-based chemotherapy for testicular cancer: Case reports and review of the literature. *Int J Cancer.* 2020;In press.
159. Pierorazio PM, Biles MJ. Indications for Surgery in Disseminated Seminoma. *Urol Clin North Am.* 2019;46(3):399-407.
160. Risk MC, Foster RS. Postchemotherapy retroperitoneal lymph node dissection for testis cancer. Expert review of anticancer therapy. 2011;11(1):95-106.
161. Fizazi K, Tjulandin S, Salvioni R, Germa-Lluch JR, Bouzy J, Ragan D, et al. Viable malignant cells after primary chemotherapy for disseminated nonseminomatous germ cell tumors: prognostic factors and role of postsurgery chemotherapy--results from an international study group. *J Clin Oncol.* 2001;19(10):2647-57.
162. Fossa SD, Ous S, Lien HH, Stenwig AE. Post-chemotherapy lymph node histology in radiologically normal patients with metastatic nonseminomatous testicular cancer. *J Urol.* 1989;141(3):557-9.
163. Kollmannsberger C, Daneshmand S, So A, Chi KN, Murray N, Moore C, et al. Management of disseminated nonseminomatous germ cell tumors with risk-based chemotherapy followed by response-guided postchemotherapy surgery. *J Clin Oncol.* 2010;28(4):537-42.
164. Ehrlich Y, Brames MJ, Beck SD, Foster RS, Einhorn LH. Long-term follow-up of Cisplatin combination chemotherapy in patients with disseminated nonseminomatous germ cell tumors: is a postchemotherapy retroperitoneal lymph node dissection needed after complete remission? *J Clin Oncol.* 2010;28(4):531-6.
165. Heidenreich A, Paffenholz P, Nestler T, Pfister D. Primary and Postchemotherapy Retroperitoneal Lymphadenectomy for Testicular Cancer. *Oncol Res Treat.* 2018;41(6):370-8.
166. Cho JS, Kaimakiotis HZ, Cary C, Masterson TA, Beck S, Foster R. Modified retroperitoneal lymph node dissection for post-chemotherapy residual tumour: a long-term update. *BJU Int.* 2017;120(1):104-8.
167. Heidenreich A, Pfister D, Witthuhn R, Thuer D, Albers P. Postchemotherapy retroperitoneal lymph node dissection in advanced testicular cancer: radical or modified template resection. *Eur Urol.* 2009;55(1):217-24.
168. Masterson TA, Cary C. The Use of Modified Templates in Early and Advanced Stage Nonseminomatous Germ Cell Tumor. *Adv Urol.* 2018;2018:6783147.
169. Gerdtsen A, Hakansson U, Tornblom M, Jancke G, Negaard HFS, Glimelius I, et al. Surgical Complications in Postchemotherapy Retroperitoneal Lymph Node Dissection for Nonseminoma Germ Cell Tumour: A Population-based Study from the Swedish Norwegian Testicular Cancer Group. *Eur Urol Oncol.* 2019.
170. Cheney SM, Andrews PE, Leibovich BC, Castle EP. Robot-assisted retroperitoneal lymph node dissection: technique and initial case series of 18 patients. *BJU Int.* 2015;115(1):114-20.
171. Stepanian S, Patel M, Porter J. Robot-assisted Laparoscopic Retroperitoneal Lymph Node Dissection for Testicular Cancer: Evolution of the Technique. *Eur Urol.* 2016;70(4):661-7.
172. Pearce SM, Golan S, Gorin MA, Luckenbaugh AN, Williams SB, Ward JF, et al. Safety and Early Oncologic Effectiveness of Primary Robotic Retroperitoneal Lymph Node Dissection for Nonseminomatous Germ Cell Testicular Cancer. *Eur Urol.* 2017;71(3):476-82.
173. Herr HW, Sheinfeld J, Puc HS, Heelan R, Bajorin DF, Mencil P, et al. Surgery for a post-chemotherapy residual mass in seminoma. *J Urol.* 1997;157(3):860-2.

174. Mosharafa AA, Foster RS, Leibovich BC, Bihle R, Johnson C, Donohue JP. Is post-chemotherapy resection of seminomatous elements associated with higher acute morbidity? *J Urol.* 2003;169(6):2126-8.
175. Hofmockel G, Gruss A, Theiss M. Chemotherapy in advanced seminoma and the role of postcytostatic retroperitoneal lymph node dissection. *Urol Int.* 1996;57(1):38-42.
176. Daneshmand S, Albers P, Fossa SD, Heidenreich A, Kollmannsberger C, Kroke S, et al. Contemporary management of postchemotherapy testis cancer. *Eur Urol.* 2012;62(5):867-76.
177. Ghodoussipour S, Daneshmand S. Surgical strategies for postchemotherapy testis cancer. *Transl Androl Urol.* 2020;9(Suppl 1):S74-S82.
178. Carver BS, Cronin AM, Eggener S, Savage CJ, Motzer RJ, Bajorin D, et al. The total number of retroperitoneal lymph nodes resected impacts clinical outcome after chemotherapy for metastatic testicular cancer. *Urology.* 2010;75(6):1431-5.
179. Thompson RH, Carver BS, Bosl GJ, Bajorin D, Motzer R, Feldman D, et al. Evaluation of lymph node counts in primary retroperitoneal lymph node dissection. *Cancer.* 2010;116(22):5243-50.
180. Donohue JP, Foster RS. Retroperitoneal lymphadenectomy in staging and treatment. The development of nerve-sparing techniques. *Urol Clin North Am.* 1998;25(3):461-8.
181. Hiestier A, Nini A, Fingerhut A, Grosse Siemer R, Winter C, Albers P, et al. Preservation of Ejaculatory Function After Postchemotherapy Retroperitoneal Lymph Node Dissection (PC-RPLND) in Patients With Testicular Cancer: Template vs. Bilateral Resection. *Front Surg.* 2018;5:80.
182. Luz MA, Kotb AF, Aldousari S, Brimo F, Tanguay S, Kassouf W, et al. Retroperitoneal lymph node dissection for residual masses after chemotherapy in nonseminomatous germ cell testicular tumor. *World J Surg Oncol.* 2010;8:97.
183. Pettus JA, Carver BS, Masterson T, Stasi J, Sheinfeld J. Preservation of ejaculation in patients undergoing nerve-sparing postchemotherapy retroperitoneal lymph node dissection for metastatic testicular cancer. *Urology.* 2009;73(2):328-31; discussion 31-2.
184. Albers P, Melchior D, Muller SC. Surgery in metastatic testicular cancer. *Eur Urol.* 2003;44(2):233-44.
185. George DW, Foster RS, Hromas RA, Robertson KA, Vance GH, Ulbright TM, et al. Update on late relapse of germ cell tumor: a clinical and molecular analysis. *J Clin Oncol.* 2003;21(1):113-22.
186. Gerl A, Clemm C, Schmeller N, Hentrich M, Lamerz R, Wilmanns W. Late relapse of germ cell tumors after cisplatin-based chemotherapy. *Ann Oncol.* 1997;8(1):41-7.
187. Oldenburg J, Wahlqvist R, Fossa SD. Late relapse of germ cell tumors. *World J Urol.* 2009;27(4):493-500.
188. Fox EP, Weathers TD, Williams SD, Loehrer PJ, Ulbright TM, Donohue JP, et al. Outcome analysis for patients with persistent nonteratomatous germ cell tumor in postchemotherapy retroperitoneal lymph node dissections. *J Clin Oncol.* 1993;11(7):1294-9.
189. Spiess PE, Brown GA, Liu P, Tannir NM, Tu SM, Evans JG, et al. Predictors of outcome in patients undergoing postchemotherapy retroperitoneal lymph node dissection for testicular cancer. *Cancer.* 2006;107(7):1483-90.
190. Eastham JA, Wilson TG, Russell C, Ahlering TE, Skinner DG. Surgical resection in patients with nonseminomatous germ cell tumor who fail to normalize serum tumor markers after chemotherapy. *Urology.* 1994;43(1):74-80.
191. Fossa SD, Stenning SP, Gerl A, Horwich A, Clark PI, Wilkinson PM, et al. Prognostic factors in patients progressing after cisplatin-based chemotherapy for malignant non-seminomatous germ cell tumours. *Br J Cancer.* 1999;80(9):1392-9.
192. Murphy BR, Breeden ES, Donohue JP, Messemmer J, Walsh W, Roth BJ, et al. Surgical salvage of chemorefractory germ cell tumors. *J Clin Oncol.* 1993;11(2):324-9.
193. Nichols CR. Treatment of recurrent germ cell tumors. *Semin Surg Oncol.* 1999;17(4):268-74.
194. Oldenburg J, Lorch A, Fossa SD. Late relapse of germ cell tumors. *Hematol Oncol Clin North Am.* 2011;25(3):615-26, x.
195. Sharp DS, Carver BS, Eggener SE, Kondagunta GV, Motzer RJ, Bosl GJ, et al. Clinical outcome and predictors of survival in late relapse of germ cell tumor. *J Clin Oncol.* 2008;26(34):5524-9.
196. Baniel J, Foster RS, Gonin R, Messemmer JE, Donohue JP, Einhorn LH. Late relapse of testicular cancer. *J Clin Oncol.* 1995;13(5):1170-6.
197. Dieckmann KP, Albers P, Classen J, De Wit M, Pichlmeier U, Rick O, et al. Late relapse of testicular germ cell neoplasms: a descriptive analysis of 122 cases. *J Urol.* 2005;173(3):824-9.
198. Herr HW, Sheinfeld J, Puc HS, Heelan R, Bajorin DF, Mencil P, et al. Surgery for a post-chemotherapy residual mass in seminoma. *J Urol.* 1997;157(3):860-2.
199. Quek ML, Simma-Chiang V, Stein JP, Pinski J, Quinn DI, Skinner DG. Postchemotherapy residual masses in advanced seminoma: current management and outcomes. *Expert Rev Anticancer Ther.* 2005;5(5):869-74.
200. Schultz SM, Einhorn LH, Conces DJ, Jr., Williams SD, Loehrer PJ. Management of postchemotherapy residual mass in patients with advanced seminoma: Indiana University experience. *J Clin Oncol.* 1989;7(10):1497-503.
201. Sakaguchi Y, Isowa N. Successful resection of mediastinal seminoma evaluated the response to induction chemotherapy with fluorodeoxyglucose-positron emission tomography. *Ann Thorac Cardiovasc Surg.* 2012;18(1):45-7.
202. Schmoll HJ. Extragonadal germ cell tumors. *Ann Oncol.* 2002;13 Suppl 4:265-72.
203. Stang A, Trabert B, Wentzensen N, Cook MB, Rusner C, Oosterhuis JW, et al. Gonadal and extragonadal germ cell tumours in the United States, 1973-2007. *Int J Androl.* 2012;35(4):616-25.

204. Trama A, Mallone S, Nicolai N, Necchi A, Schaapveld M, Gietema J, et al. Burden of testicular, paratesticular and extragonadal germ cell tumours in Europe. *Eur J Cancer*. 2012;48(2):159-69.
205. Utz DC, Buscemi MF. Extragonadal testicular tumors. *J Urol*. 1971;105(2):271-4.
206. Ueno T, Tanaka YO, Nagata M, Tsunoda H, Anno I, Ishikawa S, et al. Spectrum of germ cell tumors: from head to toe. *Radiographics*. 2004;24(2):387-404.
207. Hartmann JT, Nichols CR, Droz JP, Horwich A, Gerl A, Fossa SD, et al. Hematologic disorders associated with primary mediastinal nonseminomatous germ cell tumors. *J Natl Cancer Inst*. 2000;92(1):54-61.
208. Schneider DT, Schuster AE, Fritsch MK, Hu J, Olson T, Lauer S, et al. Multipoint imprinting analysis indicates a common precursor cell for gonadal and nongonadal pediatric germ cell tumors. *Cancer Res*. 2001;61(19):7268-76.
209. McKenney JK, Heerema-McKenney A, Rouse RV. Extragonadal germ cell tumors: a review with emphasis on pathologic features, clinical prognostic variables, and differential diagnostic considerations. *Adv Anat Pathol*. 2007;14(2):69-92.
210. Bokemeyer C, Nichols CR, Droz JP, Schmoll HJ, Horwich A, Gerl A, et al. Extragonadal germ cell tumors of the mediastinum and retroperitoneum: results from an international analysis. *J Clin Oncol*. 2002;20(7):1864-73.
211. Hartmann JT, Fossa SD, Nichols CR, Droz JP, Horwich A, Gerl A, et al. Incidence of metachronous testicular cancer in patients with extragonadal germ cell tumors. *J Natl Cancer Inst*. 2001;93(22):1733-8.
212. Hashimoto K, Fujimoto H, Kouno T, Koseki M, Yonemori K, Hirata T, et al. The incidence and management of metachronous testicular germ cell tumors in patients with extragonadal germ cell tumors. *Urol Oncol*. 2012;30(3):319-24.
213. Scholz M, Zehender M, Thalmann GN, Borner M, Thoni H, Studer UE. Extragonadal retroperitoneal germ cell tumor: evidence of origin in the testis. *Ann Oncol*. 2002;13(1):121-4.
214. Bokemeyer C, Hartmann JT, Fossa SD, Droz JP, Schmoll HJ, Horwich A, et al. Extragonadal germ cell tumors: relation to testicular neoplasia and management options. *APMIS*. 2003;111(1):49-59; discussion -63.
215. Albany C, Einhorn LH. Extragonadal germ cell tumors: clinical presentation and management. *Curr Opin Oncol*. 2013;25(3):261-5.
216. Kesler KA, Rieger KM, Hammoud ZT, Kruter LE, Perkins SM, Turrentine MW, et al. A 25-year single institution experience with surgery for primary mediastinal nonseminomatous germ cell tumors. *Ann Thorac Surg*. 2008;85(2):371-8.
217. Haugnes HS, Aass N, Fossa SD, Dahl O, Brydoy M, Aasebo U, et al. Pulmonary function in long-term survivors of testicular cancer. *J Clin Oncol*. 2009;27(17):2779-86.
218. Vuky J, Bains M, Bacik J, Higgins G, Bajorin DF, Mazumdar M, et al. Role of postchemotherapy adjunctive surgery in the management of patients with nonseminoma arising from the mediastinum. *J Clin Oncol*. 2001;19(3):682-8.
219. Busch J, Seidel C, Zengerling F. Male Extragonadal Germ Cell Tumors of the Adult. *Oncol Res Treat*. 2016;39(3):140-4.
220. Albany C, Kesler K, Cary C. Management of Residual Mass in Germ Cell Tumors After Chemotherapy. *Curr Oncol Rep*. 2019;21(1):5.
221. Lorch A, Beyer J, Bascoul-Mollevis C, Kramar A, Einhorn LH, Necchi A, et al. Prognostic factors in patients with metastatic germ cell tumors who experienced treatment failure with cisplatin-based first-line chemotherapy. *J Clin Oncol*. 2010;28(33):4906-11.
222. Kondagunta GV, Bacik J, Donadio A, Bajorin D, Marion S, Sheinfeld J, et al. Combination of paclitaxel, ifosfamide, and cisplatin is an effective second-line therapy for patients with relapsed testicular germ cell tumors. *J Clin Oncol*. 2005;23(27):6549-55.
223. McCaffrey JA, Mazumdar M, Bajorin DF, Bosl GJ, Vlamis V, Motzer RJ. Ifosfamide- and cisplatin-containing chemotherapy as first-line salvage therapy in germ cell tumors: response and survival. *J Clin Oncol*. 1997;15(7):2559-63.
224. Kollmannsberger C, Beyer J, Liersch R, Schoeffski P, Metzner B, Hartmann JT, et al. Combination chemotherapy with gemcitabine plus oxaliplatin in patients with intensively pretreated or refractory germ cell cancer: a study of the German Testicular Cancer Study Group. *J Clin Oncol*. 2004;22(1):108-14.
225. De Giorgi U, Rosti G, Aieta M, Testore F, Burattini L, Fornarini G, et al. Phase II study of oxaliplatin and gemcitabine salvage chemotherapy in patients with cisplatin-refractory nonseminomatous germ cell tumor. *Eur Urol*. 2006;50(5):1032-8; discussion 8-9.
226. Pectasides D, Pectasides M, Farmakis D, Aravantinos G, Nikolaou M, Koumpou M, et al. Gemcitabine and oxaliplatin (GEMOX) in patients with cisplatin-refractory germ cell tumors: a phase II study. *Ann Oncol*. 2004;15(3):493-7.
227. Einhorn LH, Brame MJ, Juliar B, Williams SD. Phase II study of paclitaxel plus gemcitabine salvage chemotherapy for germ cell tumors after progression following high-dose chemotherapy with tandem transplant. *J Clin Oncol*. 2007;25(5):513-6.
228. Bokemeyer C, Oechsle K, Honecker F, Mayer F, Hartmann JT, Waller CF, et al. Combination chemotherapy with gemcitabine, oxaliplatin, and paclitaxel in patients with cisplatin-refractory or multiply relapsed germ-cell tumors: a study of the German Testicular Cancer Study Group. *Ann Oncol*. 2008;19(3):448-53.
229. De Giorgi U, Rosti G, Papiani G, Aieta M, Fochessati F, Paoluzzi L, et al. Weekly gemcitabine, paclitaxel, oxaliplatin combination chemotherapy in patients with Cisplatin-refractory germ cell tumor: preliminary experience. *Am J Clin Oncol*. 2004;27(5):457-60.

230. Pectasides D, Pectasides M, Farmakis D, Aravantinos G, Nikolaou M, Koumpou M, et al. Oxaliplatin and irinotecan plus granulocyte-colony stimulating factor as third-line treatment in relapsed or cisplatin-refractory germ-cell tumor patients: a phase II study. *Eur Urol*. 2004;46(2):216-21.
231. Nicolai N, Necchi A, Gianni L, Piva L, Biasoni D, Torelli T, et al. Long-term results of a combination of paclitaxel, cisplatin and gemcitabine for salvage therapy in male germ-cell tumours. *BJU Int*. 2009;104(3):340-6.
232. Raggi D, Giannatempo P, Miceli R, Fare E, Piva L, Biasoni D, et al. Etoposide, Methotrexate, and Dactinomycin Alternating With Cyclophosphamide and Vincristine (EMACO) for Male Patients With HCG-expressing, Chemoresistant Germ Cell Tumors. *Am J Clin Oncol*. 2017;40(1):60-5.
233. Einhorn LH, Williams SD, Chamness A, Brames MJ, Perkins SM, Abonour R. High-dose chemotherapy and stem-cell rescue for metastatic germ-cell tumors. *N Engl J Med*. 2007;357(4):340-8.
234. Oing C, Giannatempo P, Honecker F, Oechsle K, Bokemeyer C, Beyer J. Palliative treatment of germ cell cancer. *Cancer Treat Rev*. 2018;71:102-7.
235. Miller JC, Einhorn LH. Phase II study of daily oral etoposide in refractory germ cell tumors. *Semin Oncol*. 1990;17(1 Suppl 2):36-9.
236. Vaughn DJ, Hwang WT, Lal P, Rosen MA, Gallagher M, O'Dwyer PJ. Phase 2 trial of the cyclin-dependent kinase 4/6 inhibitor palbociclib in patients with retinoblastoma protein-expressing germ cell tumors. *Cancer*. 2015;121(9):1463-8.
237. Adra N, Einhorn LH, Althouse SK, Ammakkanavar NR, Musapatika D, Albany C, et al. Phase II trial of pembrolizumab in patients with platinum refractory germ-cell tumors: a Hoosier Cancer Research Network Study GU14-206. *Ann Oncol*. 2018;29(1):209-14.
238. Necchi A, Lo Vullo S, Giannatempo P, Raggi D, Calareso G, Togliardi E, et al. Pazopanib in advanced germ cell tumors after chemotherapy failure: results of the open-label, single-arm, phase 2 Pazotest trial. *Ann Oncol*. 2017;28(6):1346-51.
239. Fossa SD, Aass N, Harvei S, Tretli S. Increased mortality rates in young and middle-aged patients with malignant germ cell tumours. *Br J Cancer*. 2004;90(3):607-12.
240. Fossa SD, Gilbert E, Dores GM, Chen J, McGlynn KA, Schonfeld S, et al. Noncancer causes of death in survivors of testicular cancer. *J Natl Cancer Inst*. 2007;99(7):533-44.
241. Kvammen O, Myklebust TA, Solberg A, Moller B, Klepp OH, Fossa SD, et al. Long-term Relative Survival after Diagnosis of Testicular Germ Cell Tumor. *Cancer Epidemiol Biomarkers Prev*. 2016;25(5):773-9.
242. van den Belt-Dusebout AW, Nuver J, de Wit R, Gietema JA, ten Bokkel Huinink WW, Rodrigus PT, et al. Long-term risk of cardiovascular disease in 5-year survivors of testicular cancer. *J Clin Oncol*. 2006;24(3):467-75.
243. Haugnes HS, Wethal T, Aass N, Dahl O, Klepp O, Langberg CW, et al. Cardiovascular risk factors and morbidity in long-term survivors of testicular cancer: a 20-year follow-up study. *J Clin Oncol*. 2010;28(30):4649-57.
244. Huddart RA, Norman A, Shahidi M, Horwich A, Coward D, Nicholls J, et al. Cardiovascular disease as a long-term complication of treatment for testicular cancer. *J Clin Oncol*. 2003;21(8):1513-23.
245. Haugnes HS, Aass N, Fossa SD, Dahl O, Klepp O, Wist EA, et al. Components of the metabolic syndrome in long-term survivors of testicular cancer. *Ann Oncol*. 2007;18(2):241-8.
246. Nuver J, Smit AJ, Wolffenbuttel BH, Sluiter WJ, Hoekstra HJ, Sleijfer DT, et al. The metabolic syndrome and disturbances in hormone levels in long-term survivors of disseminated testicular cancer. *J Clin Oncol*. 2005;23(16):3718-25.
247. Wethal T, Kjekshus J, Roislien J, Ueland T, Andreassen AK, Wergeland R, et al. Treatment-related differences in cardiovascular risk factors in long-term survivors of testicular cancer. *J Cancer Surviv*. 2007;1(1):8-16.
248. Nuver J, Smit AJ, Sleijfer DT, van Gessel AI, van Roon AM, van der Meer J, et al. Microalbuminuria, decreased fibrinolysis, and inflammation as early signs of atherosclerosis in long-term survivors of disseminated testicular cancer. *Eur J Cancer*. 2004;40(5):701-6.
249. Andreassen KE, Grotmol T, Cvancarova MS, Johannesen TB, Fossa SD. Risk of metachronous contralateral testicular germ cell tumors: a population-based study of 7,102 Norwegian patients (1953-2007). *Int J Cancer*. 2011;129(12):2867-74.
250. Kvammen O, Myklebust TA, Solberg A, Moller B, Klepp OH, Fossa SD, et al. Causes of inferior relative survival after testicular germ cell tumor diagnosed 1953-2015: A population-based prospective cohort study. *PLoS One*. 2019;14(12):e0225942.
251. Fung C, Fossa SD, Milano MT, Oldenburg J, Travis LB. Solid tumors after chemotherapy or surgery for testicular nonseminoma: a population-based study. *J Clin Oncol*. 2013;31(30):3807-14.
252. Kier MG, Hansen MK, Lauritsen J, Mortensen MS, Bandak M, Agerbaek M, et al. Second Malignant Neoplasms and Cause of Death in Patients With Germ Cell Cancer: A Danish Nationwide Cohort Study. *JAMA Oncol*. 2016;2(12):1624-7.
253. Groot HJ, Lubberts S, de Wit R, Witjes JA, Kerst JM, de Jong IJ, et al. Risk of Solid Cancer After Treatment of Testicular Germ Cell Cancer in the Platinum Era. *J Clin Oncol*. 2018;36(24):2504-13.
254. Del Risco Kollerud R, Blaasaas KG, Claussen B, Nafstad P, Cannon-Albright LA, Ruud E, et al. Family history of cancer and the risk of childhood solid tumours: a Norwegian nationwide register-based cohort study. *Br J Cancer*. 2018;118(6):905-12.
255. Moller H, Skakkebaek NE. Risk of testicular cancer in subfertile men: case-control study. *BMJ*. 1999;318(7183):559-62.

256. DeSantis M, Albrecht W, Holtl W, Pont J. Impact of cytotoxic treatment on long-term fertility in patients with germ-cell cancer. *Int J Cancer*. 1999;83(6):864-5.
257. Brydoy M, Fossa SD, Klepp O, Bremnes RM, Wist EA, Wentzel-Larsen T, et al. Paternity following treatment for testicular cancer. *J Natl Cancer Inst*. 2005;97(21):1580-8.
258. Ghezzi M, Berretta M, Bottacin A, Palego P, Sartini B, Cosci I, et al. Impact of Bep or Carboplatin Chemotherapy on Testicular Function and Sperm Nucleus of Subjects with Testicular Germ Cell Tumor. *Front Pharmacol*. 2016;7:122.
259. Al-Jebari Y, Glimelius I, Berglund Nord C, Cohn-Cedermark G, Stahl O, Tandstad T, et al. Cancer therapy and risk of congenital malformations in children fathered by men treated for testicular germ-cell cancer: A nationwide register study. *PLoS Med*. 2019;16(6):e1002816.
260. Jacobsen KD, Ous S, Waehre H, Trasti H, Stenwig AE, Lien HH, et al. Ejaculation in testicular cancer patients after post-chemotherapy retroperitoneal lymph node dissection. *Br J Cancer*. 1999;80(1-2):249-55.
261. Kamischke A, Nieschlag E. Update on medical treatment of ejaculatory disorders. *Int J Androl*. 2002;25(6):333-44.
262. Nord C, Bjoro T, Ellingsen D, Mykletun A, Dahl O, Klepp O, et al. Gonadal hormones in long-term survivors 10 years after treatment for unilateral testicular cancer. *Eur Urol*. 2003;44(3):322-8.
263. Svartberg J, von Muhlen D, Schirmer H, Barrett-Connor E, Sundfjord J, Jorde R. Association of endogenous testosterone with blood pressure and left ventricular mass in men. The Tromso Study. *Eur J Endocrinol*. 2004;150(1):65-71.
264. Laaksonen DE, Niskanen L, Punnonen K, Nyssonen K, Tuomainen TP, Valkonen VP, et al. Testosterone and sex hormone-binding globulin predict the metabolic syndrome and diabetes in middle-aged men. *Diabetes care*. 2004;27(5):1036-41.
265. Shores MM, Matsumoto AM, Sloan KL, Kivlahan DR. Low serum testosterone and mortality in male veterans. *Arch Intern Med*. 2006;166(15):1660-5.
266. Laughlin GA, Barrett-Connor E, Bergstrom J. Low serum testosterone and mortality in older men. *J Clin Endocrinol Metab*. 2008;93(1):68-75.
267. Gupta SK, Lindemulder EA, Sathyan G. Modeling of circadian testosterone in healthy men and hypogonadal men. *J Clin Pharmacol*. 2000;40(7):731-8.
268. Bjerner J, Biernat D, Fossa SD, Bjoro T. Reference intervals for serum testosterone, SHBG, LH and FSH in males from the NORIP project. *Scand J Clin Lab Invest*. 2009;69(8):873-9 e1-11.
269. Oechsle K, Hartmann M, Mehnert A, Oing C, Bokemeyer C, Vehling S. Symptom burden in long-term germ cell tumor survivors. *Support Care Cancer*. 2016;24(5):2243-50.
270. Bower JE, Bak K, Berger A, Breitbart W, Escalante CP, Ganz PA, et al. Screening, assessment, and management of fatigue in adult survivors of cancer: an American Society of Clinical oncology clinical practice guideline adaptation. *J Clin Oncol*. 2014;32(17):1840-50.
271. Sprauten M, Haugnes HS, Brydoy M, Kiserud C, Tandstad T, Bjoro T, et al. Chronic fatigue in 812 testicular cancer survivors during long-term follow-up: increasing prevalence and risk factors. *Ann Oncol*. 2015;26(10):2133-40.
272. Adams SC, DeLorey DS, Davenport MH, Fairey AS, North S, Courneya KS. Effects of high-intensity interval training on fatigue and quality of life in testicular cancer survivors. *Br J Cancer*. 2018;118(10):1313-21.
273. Zhou ES, Hall KT, Michaud AL, Blackmon JE, Partridge AH, Recklitis CJ. Open-label placebo reduces fatigue in cancer survivors: a randomized trial. *Support Care Cancer*. 2019;27(6):2179-87.
274. Hoenemeyer TW, Kaptchuk TJ, Mehta TS, Fontaine KR. Open-Label Placebo Treatment for Cancer-Related Fatigue: A Randomized-Controlled Clinical Trial. *Sci Rep*. 2018;8(1):2784.
275. Fossa SD, Aass N, Winderen M, Bormer OP, Olsen DR. Long-term renal function after treatment for malignant germ-cell tumours. *Ann Oncol*. 2002;13(2):222-8.
276. Brydoy M, Oldenburg J, Klepp O, Bremnes RM, Wist EA, Wentzel-Larsen T, et al. Observational study of prevalence of long-term Raynaud-like phenomena and neurological side effects in testicular cancer survivors. *J Natl Cancer Inst*. 2009;101(24):1682-95.
277. Widen SE, Erlandsson SI. Self-reported tinnitus and noise sensitivity among adolescents in Sweden. *Noise & health*. 2004;7(25):29-40.
278. Frisina RD, Wheeler HE, Fossa SD, Kerns SL, Fung C, Sesso HD, et al. Comprehensive Audiometric Analysis of Hearing Impairment and Tinnitus After Cisplatin-Based Chemotherapy in Survivors of Adult-Onset Cancer. *J Clin Oncol*. 2016;34(23):2712-20.
279. Haugnes HS, Stenklev NC, Brydoy M, Dahl O, Wilsaard T, Laukli E, et al. Hearing loss before and after cisplatin-based chemotherapy in testicular cancer survivors: a longitudinal study. *Acta Oncol*. 2018;57(8):1075-83.
280. Albers P, Siener R, Krege S, Schmelz H-U, Dieckmann K-P, Heidenreich A, et al. Randomized Phase III Trial Comparing Retroperitoneal Lymph Node Dissection With One Course of Bleomycin and Etoposide Plus Cisplatin Chemotherapy in the Adjuvant Treatment of Clinical Stage I Nonseminomatous Testicular Germ Cell Tumors: AUO Trial AH 01/94 by the German Testicular Cancer Study Group. *J Clin Oncol*. 2008;JCO.2007.12.0899.
281. Smith EM, Pang H, Cirrincione C, Fleishman S, Paskett ED, Ahles T, et al. Effect of duloxetine on pain, function, and quality of life among patients with chemotherapy-induced painful peripheral neuropathy: a randomized clinical trial. *JAMA*. 2013;309(13):1359-67.

282. Jordan B, Margulies A, Cardoso F, Cavaletti G, Haugnes HS, Jahn P, et al. Systemic anticancer therapy-induced peripheral and central neurotoxicity: ESMO-EONS-EANO Clinical Practice Guidelines for diagnosis, prevention, treatment and follow-up. *Ann Oncol*. 2020;31(10):1306-19.
283. Hinze AM, Wigley FM. Pharmacotherapy Options in the Management of Raynaud's Phenomenon. *Curr Treatm Opt Rheumatol*. 2018;4(3):235-54.
284. Moch H, Cubilla AL, Humphrey PA, Reuter VE, Ulbright TM. The 2016 WHO Classification of Tumours of the Urinary System and Male Genital Organs-Part A: Renal, Penile, and Testicular Tumours. *Eur Urol*. 2016;70(1):93-105.
285. Ruf CG, Sanatgar N, Isbarn H, Ruf B, Simon J, Fankhauser CD, et al. Leydig-cell tumour of the testis: retrospective analysis of clinical and therapeutic features in 204 cases. *World J Urol*. 2020.
286. Fankhauser CD, Grogg JB, Hayoz S, Wettstein MS, Dieckmann KP, Sulser T, et al. Risk Factors and Treatment Outcomes of 1,375 Patients with Testicular Leydig Cell Tumors: Analysis of Published Case Series Data. *J Urol*. 2020;203(5):949-56.
287. Mineur P, De Cooman S, Hustin J, Verhoeven G, De Hertogh R. Feminizing testicular Leydig cell tumor: hormonal profile before and after unilateral orchidectomy. *J Clin Endocrinol Metab*. 1987;64(4):686-91.
288. Rutgers JL, Young RH, Scully RE. The testicular "tumor" of the adrenogenital syndrome. A report of six cases and review of the literature on testicular masses in patients with adrenocortical disorders. *Am J Surg Pathol*. 1988;12(7):503-13.
289. Paffenholz P, Pfister D, Heidenreich A. Testis-preserving strategies in testicular germ cell tumors and germ cell neoplasia in situ. *Transl Androl Urol*. 2020;9(Suppl 1):S24-S30.
290. Di Tonno F, Tavolini IM, Belmonte P, Bertoldi R, Cossaro E, Curti P, et al. Lessons from 52 patients with leydig cell tumor of the testis: the GUONE (North-Eastern Uro-Oncological Group, Italy) experience. *Urol Int*. 2009;82(2):152-7.
291. Calaway AC, Tachibana I, Masterson TA, Foster RS, Einhorn LH, Cary C. Oncologic Outcomes Following Surgical Management of Clinical Stage II Sex Cord Stromal Tumors. *Urology*. 2019;127:74-9.
292. Mooney KL, Kao CS. A Contemporary Review of Common Adult Non-germ Cell Tumors of the Testis and Paratestis. *Surg Pathol Clin*. 2018;11(4):739-58.
293. Grogg J, Schneider K, Bode PK, Kranzbuhler B, Eberli D, Sulser T, et al. Sertoli Cell Tumors of the Testes: Systematic Literature Review and Meta-Analysis of Outcomes in 435 Patients. *Oncologist*. 2020.
294. Grogg JB, Schneider K, Bode PK, Kranzbuhler B, Eberli D, Sulser T, et al. Risk factors and treatment outcomes of 239 patients with testicular granulosa cell tumors: a systematic review of published case series data. *J Cancer Res Clin Oncol*. 2020;146(11):2829-41.
295. Zhang M, Kao CS, Ulbright TM, Epstein JI. Testicular fibrothecoma: a morphologic and immunohistochemical study of 16 cases. *Am J Surg Pathol*. 2013;37(8):1208-14.
296. Roth LM, Cheng L. Classical gonadoblastoma: its relationship to the 'dissecting' variant and undifferentiated gonadal tissue. *Histopathology*. 2018;72(4):545-55.
297. Hu R, Ulbright TM, Young RH. Spermatocytic Seminoma: A Report of 85 Cases Emphasizing Its Morphologic Spectrum Including Some Aspects Not Widely Known. *Am J Surg Pathol*. 2019;43(1):1-11.
298. Sharmeen F, Rosenthal MH, Howard SA. The management of retroperitoneal lymphadenopathy in spermatocytic seminoma of the testicle. *Clin Imaging*. 2014;38(2):202-4.
299. Measurements IICoRUa. Prescribing, recording and reporting photon beam therapy (Supplement to ICRU Report 50). ICRU Report 62. Oxford University Press, Oxford, United Kingdom 1999.
300. ICRU ICoRUaM. Prescribing, recording and reporting photon beam therapy report 50. Oxford University Press, Oxford, United Kingdom; 1993.
301. ICRU ICoRUaM. Prescribing, recording, and reporting photon-beam intensity-modulated radiation therapy (IMRT). ICRU Report 83. J ICRU2010. p. pp. 1-106.
302. Zilli T, Boudreau C, Doucet R, Alizadeh M, Lambert C, van Nguyen T, et al. Bone marrow-sparing intensity-modulated radiation therapy for Stage I seminoma. *Acta Oncol*. 2011;50(4):555-62.
303. Hall EJ, Wu CS. Radiation-induced second cancers: the impact of 3D-CRT and IMRT. *Int J Radiat Oncol Biol Phys*. 2003;56(1):83-8.
304. Simone CB, 2nd, Kramer K, O'Meara WP, Bekelman JE, Belard A, McDonough J, et al. Predicted rates of secondary malignancies from proton versus photon radiation therapy for stage I seminoma. *Int J Radiat Oncol Biol Phys*. 2012;82(1):242-9.
305. Bamberg M, Schmidberger H, Meisner C, Classen J, Souchon R, Weinknecht S, et al. Radiotherapy for stages I and IIA/B testicular seminoma. *Int J Cancer*. 1999;83(6):823-7.
306. Wilder RB, Buyyounouski MK, Efstathiou JA, Beard CJ. Radiotherapy treatment planning for testicular seminoma. *Int J Radiat Oncol Biol Phys*. 2012;83(4):e445-52.